

Metronomic Therapy with Cyclophosphamide and Piroxicam Effectively Delays Tumor Recurrence in Dogs with Incompletely Resected Soft Tissue Sarcomas

R.E. Elmslie, P. Glawe, and S.W. Dow

Background: Continuous administration of low doses of cyclophosphamide and standard doses of cyclooxygenase-inhibiting drugs has been shown to suppress tumor angiogenesis, reverse immunosuppression, and deplete regulatory T cells in cancer models.

Hypothesis: We hypothesized that continuous treatment with low-dose cyclophosphamide and full-dose piroxicam would delay tumor recurrence in dogs with soft tissue sarcomas (STS).

Animals: Eighty-five dogs with incompletely resected STS, 30 treated dogs, and 55 contemporary control dogs.

Methods: Treatment outcomes in 85 dogs with incompletely resected STS were evaluated in a retrospective study. Dogs in the treatment group received continuously administered low-dose cyclophosphamide (10 mg/m²) and standard dose piroxicam (0.3 mg/kg) therapy. Time to local tumor recurrence (disease-free interval; DFI) was compared between the 30 treated dogs and 55 untreated control dogs matched for age and tumor site and grade.

Results: DFI was significantly ($P < .0001$) prolonged for STS of all sites (trunk and extremity) in treated dogs compared with untreated control dogs. The DFI also was significantly longer in treated dogs when tumor site (trunk and extremity) was compared. Twelve treated dogs (40%) experienced mild toxicity (grade 1 and 2) at some point during treatment and 1 dog developed grade 4 cystitis. Every other day dosing was tolerated better than daily dosing.

Conclusions: Metronomic therapy with cyclophosphamide and piroxicam was very effective in preventing tumor recurrence in dogs with incompletely resected STS. These findings suggest that further evaluation of this approach is warranted as adjuvant therapy in dogs with highly metastatic tumors such as osteosarcoma and melanoma.

Key words: Angiogenesis; Cancer; Chemotherapy; Cyclooxygenase.

For tumors to grow progressively and metastasize, they must be able to stimulate angiogenesis.^{1,2} Continuous administration of fixed, low doses of chemotherapy drugs without prolonged breaks in treatment (metronomic therapy) has been shown to be an effective means of inhibiting tumor angiogenesis, based primarily on studies in mice.^{3–7} The metronomic dosing strategy is based on the fact that endothelial cells are much more sensitive to continuous exposure to low doses of chemotherapeutic drugs and less likely to undergo genetic mutations than are tumor cells, which typically develop rapid drug resistance. Among the major effects of metronomically dosed chemotherapy is inhibition of mobilization of endothelial progenitor cells, which arise from the bone marrow and seed tumor tissues. These bone marrow-derived endothelial cells are a major source of new blood vessels that develop in tumors.^{5,8–10} In addition, metronomic chemotherapy also stimulates production of thrombospondin-1, a potent endogenous angiogenesis inhibitor.^{11–13}

Continuous administration of cyclophosphamide effectively inhibits angiogenesis.^{4,5,8} In addition, contin-

uous low doses of cyclophosphamide also appear to exert substantial positive effects on antitumor immunity. For example, low-dose cyclophosphamide therapy can significantly enhance CD8⁺ T-cell responses to tumor antigens, particularly in tumor-bearing animals.^{14,15} These effects may be mediated in part by depletion of regulatory T cells.^{14,16} Regulatory T cells are a subset of CD4⁺ T cells with potent immunosuppressive effects on effector T cells (both CD4⁺ and CD8⁺) and antigen presenting cells.

Cyclooxygenase-2 (COX-2), which may overexpressed by tumor cells or stromal cells, also can promote tumor growth by stimulating angiogenesis.^{17–20} For example, COX-2 overexpression is associated with increased production of angiogenic factors such as VEGF, basic fibroblast growth factor, and transforming growth factor β . In addition, recent studies suggest that COX plays an important role in both the generation of Tregs and in the regulation of their effector functions.^{21–24}

Because both metronomic cyclophosphamide chemotherapy and COX-2 inhibitors inhibit angiogenesis and suppress regulatory T cells, it has been suggested that combined therapy might elicit greater inhibition of angiogenesis and tumor growth.¹⁷ In 1 study, low-dose cyclophosphamide combined with standard doses of a selective COX-2 inhibitor (celecoxib) was evaluated in an open trial in patients with relapsed non-Hodgkin's lymphoma.²⁵ Systemic inhibition of angiogenesis, as reflected by decreased numbers of circulating endothelial progenitor cells, was noted. Metronomic dosing of treosulfan in combination with a COX-2 inhibitor (rofecoxib) was also evaluated in melanoma patients and a 4-drug trial that included celecoxib was assessed in patients with glioblastoma.^{26,27}

From the Veterinary Cancer Specialists, Englewood, CO (Elmslie, Glawe); the Department of Clinical Sciences, Animal Cancer Center (Dow), and the Department of Microbiology, Immunology, and Pathology, Colorado State University, Ft. Collins, CO (Dow).

Corresponding author: Dr Steven W. Dow, Department of Clinical Sciences, Animal Cancer Center, Colorado State University, Ft. Collins, CO 80523; e-mail: sdow@colostate.edu.

Submitted November 21, 2007; Revised February 18, 2008; Accepted August 25, 2008.

Copyright © 2008 by the American College of Veterinary Internal Medicine

10.1111/j.1939-1676.2008.0179.x

Piroxicam, a nonselective COX inhibitor, has been shown previously to elicit significant antitumor activity in dogs with transitional cell cancer.^{28–31} For example, piroxicam decreased angiogenesis and increased apoptosis in canine transitional carcinomas, both *in vitro* and *in vivo*.²⁸ Interestingly, although *cis*-platinum and piroxicam both independently have activity against transitional cell cancer in dogs, a recent study reported that the combination of both was not more effective than either alone and the combination also led to increased renal toxicity.³²

We reported recently that metronomic dosing of cyclophosphamide and etoposide, together with standard doses of piroxicam, significantly increased disease-free intervals (DFI) in dogs with completely resected splenic hemangiosarcoma, compared with treatment with doxorubicin alone.³³ However, the differences in DFI were not large and the study involved small numbers of dogs. Thus, there is precedent from studies in dogs and humans for combining metronomic chemotherapy with a COX inhibitor, but additional larger clinical trials are needed.

Therefore, we conducted a retrospective study to determine whether continuous dosing of cyclophosphamide and piroxicam was effective in inhibiting local tumor recurrence in dogs with incompletely resected soft tissue sarcomas (STS). STS in dogs are relatively slow growing tumors located primarily in the skin of the trunk and extremities.^{34–36} These tumors do not readily metastasize, but often recur locally after incomplete surgical excision.³⁵ Currently, the only known effective options for preventing tumor recurrence in dogs with incompletely resected STS are re-excision of the tumor with wide surgical margins or radiation therapy.^{35–37} The recurrence rates after a 2nd surgery are reported to be approximately 15%. However, in some cases additional surgery is not feasible and radiation therapy is not always available. Therefore, there could be substantial clinical benefit for dogs with STS if a safe and effective PO administered treatment that could prevent tumor recurrence was available. The current study was designed therefore to compare DFI in treated dogs with that of a contemporary control population of dogs with incompletely resected STS matched for tumor grade and location. The tolerability and long-term safety of the cyclophosphamide and piroxicam treatment regimen also were assessed.

Materials and Methods

Patient Population and Inclusion Criteria

Medical records from 1311 dogs with STS evaluated at a single veterinary referral center in Colorado over a 14-year period (1993–2007) were evaluated to identify eligible patients. All dogs in the study were evaluated and by 1 of 2 veterinary oncologists (RE and PG). Only patients with a biopsy-confirmed diagnosis of STS were eligible for inclusion in the study. In addition, whether the original tumor excision was done by a general practice veterinarian or by a board-certified veterinary surgeon was noted. Owners were offered the choice of participating in the metronomic chemotherapy study and made the decision in consultation with their veterinary oncologist.

Criteria for inclusion in the study included the following: a histologic diagnosis of STS along with histologic grading (grade 1–3); tumor in a subcutaneous location; microscopic evidence of residual tumor at the margins of resected tumor tissue (ie, incompletely resected tumor); no additional treatment other than surgery alone or surgery plus cyclophosphamide and piroxicam; and a known surgery date. Tumor margins were evaluated by board-certified veterinary pathologists. In the case of animals with multiple tumor recurrences, only data for the time of 1st tumor recurrence were recorded.

Treatment Dosing and Schedule

Dogs were treated with a 2-drug combination consisting of PO administered low-dose cyclophosphamide (10 mg/m²) and full-dose piroxicam (0.3 mg/kg). The drugs initially were administered daily to all treated dogs. In cases where unacceptable adverse effects developed, the dosing interval was increased to every other day. Both piroxicam and cyclophosphamide were compounded at 1 of 3 compounding pharmacies in the Denver area. Dogs treated with metronomic therapy were re-evaluated at 3-month intervals throughout their treatment period. Follow-up times for the control treatment population were at longer intervals and generally not regularly scheduled.

Statistical Analysis

DFI curves were plotted using Kaplan-Meier analysis. The DFI curves then were compared statistically using the log-rank test (Mantel-Haenszel test). Differences in DFI were considered statistically significant for *P*-values < .05. Data were analyzed using GraphPad Prism software.³⁸

Results

Study Population Characteristics

From review of 1,311 medical records of dogs with STS treated over a 14-year period, 85 eligible dogs were identified. There were 55 eligible control dogs that had incompletely resected STS of the trunk or extremity that did not receive additional treatment between the time of initial surgical tumor excision and tumor recurrence. There were 30 dogs with STS treated with continuous low-dose cyclophosphamide and full-dose piroxicam therapy eligible for inclusion in the study. Treatment with the cyclophosphamide and piroxicam regimen did not begin until the year 2001.

The general characteristics of the 2 populations are reported in Table 1. The median age of control dogs was 10 years (range, 5–15 years) and in the treated group the median age was 11 years (range, 5–15 years). The median weight was 25 kg (range, 6–45 kg) in the control group and 25 kg (range, 10–45 kg) in the treated group. There were 28 neutered male dogs and 27 spayed female dogs in the control group and 15 neutered male dogs and 15 spayed female dogs in the treated group.

We also determined whether the initial tumor excision was done by a general practitioner or by a board-certified veterinary surgeon. Although all dogs in this study had evidence of incomplete tumor resection (ie, microscopic evidence of tumor cells at the margins of the resected tumor tissue), we considered the skill of the surgeon to be an important variable in this study. In the control population, 54 of 55 surgeries were performed by general

Table 1. Patient population characteristics in dogs with incompletely resected soft tissue sarcoma treated with continuous cyclophosphamide and piroxicam therapy (30 dogs) or disease-matched untreated control dogs (55 dogs).

Parameter	Control (n = 55)	Treated (n = 30)
Age	10 years (5–15 years)	11 years (5–15 years)
Weight	25 kg (6–45 kg)	25 kg (10–45 kg)
Gender	28 CM/ 27 SF	15 CM/ 15 SF

Median values and ranges for the age and weight of the control and treated populations of dogs with incompletely resected STS are listed, along with the gender distribution.

CM, castrated male; SF, spayed female.

practitioners and 1 by a board-certified veterinary surgeon. In the treated population, 22 of 30 surgeries were performed by general practitioners and 8 of 30 surgeries by board-certified veterinary surgeons.

Tumor characteristics

The tumor characteristics of the control and treated populations also were compared (Table 2). Slides were reviewed by 1 of several board-certified veterinary pathologists. Twenty-nine of 55 tumors (53%) were on the extremities in the control group and 26 of 55 tumors (47%) were on the trunk, whereas 19 of 30 tumors (63%) were on the extremities in the treated group and 11 of 30 (37%) were on the trunk. The majority of STS tumors were grade II (68 and 77%, respectively) in the control and treated groups. We compared the distribution of tumors based on tumor stage between control and treated populations by Fisher’s exact test and found no significant differences (grade I, $P = .80$; grade II, $P = .73$; grade III, $P = .66$). The most common tumor was hemangiopericytoma or peripheral nerve sheath tumor in both groups of dogs (43 of 55 [78%] in the control group and 24 of 30 [80%] in the treated group).

Comparison of DFI in Control versus Treated Dogs

In the 1st analysis, the DFI for all patients, regardless of tumor location or treating veterinarian (general prac-

Table 2. Tumor characteristics in 85 dogs with incompletely resected soft tissue sarcomas.

Tumor Parameter	Control Dogs (n = 55)	Treated Dogs (n = 30)
Tumor on extremity	29/55 (53%)	19/30 (63%)
Tumor on trunk	26/55 (47%)	11/30 (37%)
Grade 1	14/55 (25%)	6/30 (20%)
Grade 2	37/55 (68%)	23/30 (77%)
Grade 3	4/55 (7%)	1/30 (3%)
Histology (HPC or PNST)	43/55 (78%)	24/30 (80%)
Histology (neurofibrosarcoma)	4/55 (7%)	1/30 (3%)
Histology (fibrosarcoma)	4/55 (7%)	1/30 (3%)
Histology (all other types)	4/55 (7%)	4/30 (13%)

HPC, hemangiopericytoma; PNST, peripheral nerve sheath tumor.

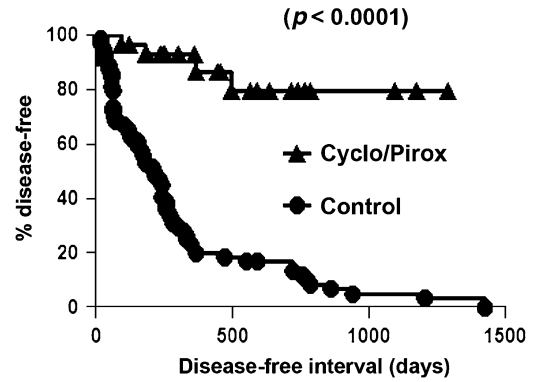


Fig 1. Disease-free interval curves for 30 treated and 55 control dogs with incompletely resected soft tissue sarcomas, regardless of tumor location. Kaplan-Meier curves were generated using disease-free interval (DFI) data for 30 dogs treated with continuous cyclophosphamide and piroxicam therapy and for 55 age and disease-matched control dogs, as described in ‘Materials and methods.’ The DFI curves were compared statistically using log-rank analysis. The DFI in dogs treated with metronomic cyclophosphamide and piroxicam therapy was significantly increased ($P < .0001$) compared with control dogs.

titioner versus board-certified veterinary surgeon), was compared. The DFI was significantly ($P < .0001$) longer in treated dogs than in control dogs, as assessed by log-rank analysis (Fig 1). The median DFI in control dogs was 211 days, whereas the median was not reached in the treated population. We calculated that if all remaining treated dogs were to develop recurrence at the time this study was submitted for publication, the predicted minimum DFI would be 410 days.

Next, we compared DFI for dogs with tumors of the extremities. For this analysis, we excluded all dogs whose tumors had been resected by board-certified veterinary surgeons to remove any possible confounding bias created by the nature of the original surgery. Thus, 27 dogs in the control group and 14 dogs in the treated group were compared. Again, we found a highly significant ($P < .0005$) difference in DFI for treated dogs compared with control dogs (Fig 2). When the analysis was repeated including all dogs with STS of the extremities, regardless of surgeon status, the differences remained highly significant ($P < .0005$; data not shown).

A similar analysis of DFI was done for dogs with STS of the trunk, again excluding dogs whose tumors had been resected by board-certified veterinary surgeons. Here again, there was a significant ($P < .005$) difference in DFI for treated dogs compared with control dogs (Fig 3).

Finally, we repeated the analysis of DFI for all STS (extremity and trunk) using only control dogs that had been treated since the year 2001 (49 dogs). This was done to eliminate possible bias that may have been introduced by use of a control population that was not matched temporally to the treated population. When the 2 contemporary populations were compared, the DFI curves remained highly significantly ($P < .0001$) different (Fig 4).

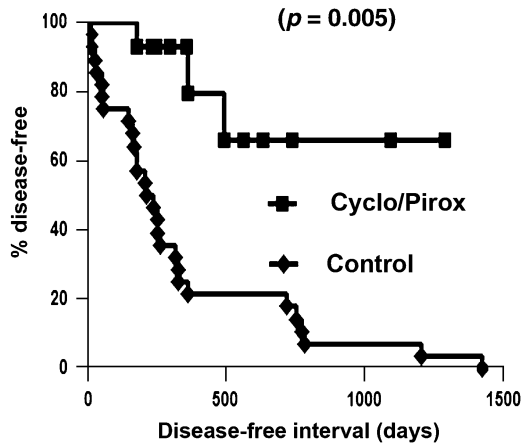


Fig 2. Disease-free interval (DFI) curves for treated and control dogs with soft tissue sarcomas (STS) of the extremities. Kaplan-Meier curves were generated using DFI data for dogs with STS of the extremities. For this analysis, dogs with surgeries performed by board-certified veterinary surgeons were excluded from the analysis, as noted in ‘Materials and methods.’ The DFI curves were compared statistically using log-rank analysis. The DFI for dogs with STS of the extremities treated with metronomic cyclophosphamide and piroxicam therapy was significantly increased ($P < .0005$) compared with control dogs.

Safety and Tolerability of the Cyclophosphamide and Piroxicam Regimen

The medical records of the 30 dogs treated with cyclophosphamide and piroxicam were examined for evidence of adverse-effects (Table 3). We found that 40% of treated dogs (12 of 30) developed adverse effects that were considered treatment related. The adverse effects were generally mild (grade 1 or 2) as assessed using a previously published grading scale.³⁸ The most common adverse effects were anorexia or vomiting (7 of 30 dogs). Two of

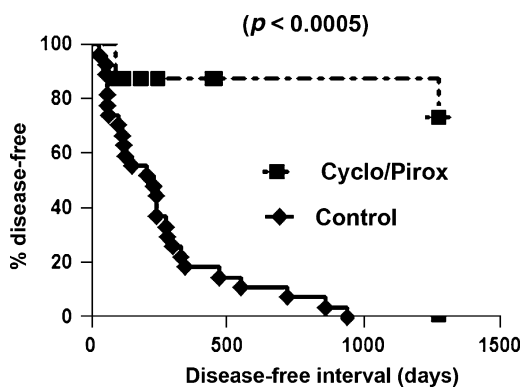


Fig 3. Disease-free interval (DFI) curves for treated and control dogs with soft tissue sarcomas (STS) of the trunk. Kaplan-Meier curves were generated using DFI data for dogs with STS of the trunk. For this analysis, dogs with surgeries performed by board-certified veterinary surgeons were excluded from the analysis, as noted in ‘Materials and methods.’ The DFI curves were compared statistically using log-rank analysis. The DFI for dogs with STS of the trunk treated with metronomic cyclophosphamide and piroxicam therapy was significantly increased ($P < .0005$) compared with control dogs.

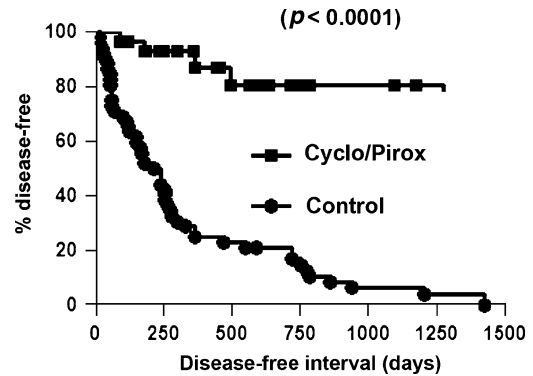


Fig 4. Disease-free interval (DFI) curves for treated dogs with soft tissue sarcomas (STS) compared with a contemporary control population of dogs with STS. Kaplan-Meier curves were generated using DFI data for dogs with STS of the extremities. For this analysis, only control dogs with STS evaluated since the year 2001 were evaluated. The DFI curves were compared statistically using log-rank analysis. The DFI for dogs with STS treated with metronomic cyclophosphamide and piroxicam therapy was significantly increased ($P < .0001$) compared with contemporary control dogs.

30 dogs had increases in serum creatinine concentration during treatment, which returned to pretreatment concentrations when the piroxicam dosing interval was increased to every other day. Three of 30 dogs developed sterile hemorrhagic cystitis. In 2 dogs, the cystitis was considered a grade 2 toxicity, whereas in 1 dog, a grade 4 toxicity developed due to severe dysuria that eventually necessitated euthanasia. With the exception of the dog that developed severe cystitis, none of the adverse effects required discontinuation of drug treatment. In most cases the adverse effects were managed by increasing the treatment interval for both piroxicam and cyclophosphamide from daily to every other day treatment. It was not possible to determine whether switching to an every other day treatment regimen affected treatment outcomes.

Discussion

The striking inhibition of tumor recurrence that was found in dogs treated with the continuous low-dose cyclophosphamide and full-dose piroxicam treatment regimen in this study suggests that this 2-drug regimen was very effective in inhibiting the regrowth of microscopic tumor foci in dogs with STS. All control dogs in this study with incompletely resected STS had tumor recurrence, with a median DFI of 211 days. These data

Table 3. Adverse effects of continuous treatment with cyclophosphamide and piroxicam in 30 dogs with soft tissue sarcoma.

Adverse Effect	Frequency	Toxicity Grade
Anorexia	5/30 (17%)	Grade 2
Vomiting	1/30 (3%)	Grade 1
Vomiting	1/30 (3%)	Grade 2
Increased creatinine	2/30 (7%)	Grade 2
Hemorrhagic cystitis	2/30 (7%)	Grade 2
Hemorrhagic cystitis	1/30 (3%)	Grade 4

illustrate clearly the strong propensity for these tumors to recur locally. In contrast, the predicted minimal median DFI for all treated dogs was 410 days. Although the median DFI was not reached for the treated dogs, including any of the subgroups analyzed, statistical analysis indicated that the DFI curves were significantly different.

We believe these results are important inasmuch as this is the 1st study to assess the effects of metronomic therapy with cyclophosphamide and piroxicam in a large population of dogs with cancer. Although many veterinary oncologists use low-dose cyclophosphamide and piroxicam protocols to treat a variety of tumors, to date there have been no published studies examining the efficacy of this approach.

The inhibition of tumor regrowth observed in this study was likely due to the combined effects of angiogenesis inhibition and restoration of immune function, although those mechanisms were not assessed here. Two previous studies in humans have examined the effects of metronomic cyclophosphamide plus a COX-2 inhibitor on angiogenesis in patients with cancer, with 1 study reporting positive results and the other study reporting negative results.^{25,39} In both studies, the effects of treatment on angiogenesis were assessed by measuring numbers of circulating endothelial progenitor cells. Previous studies also have shown that measurement of circulating endothelial progenitor cells provides one of the best correlates with systemic angiogenesis inhibition after metronomic chemotherapy.^{8,10} It is now possible to measure circulating endothelial cell progenitors in dogs, as reported recently, and this would be a very important parameter of treatment effects to measure in future studies of metronomic chemotherapy in dogs.⁴⁰ In 1 clinical study, continuous administration of cyclophosphamide was shown to deplete regulatory T cells in human patients, though studies examining the combined effects of low-dose chemotherapy and COX inhibition have not been reported.¹⁶ Finally, it cannot be excluded that continuous treatment with very low doses of cyclophosphamide may induce direct antitumor effects, although there is no precedent for this from rodent studies performed to date.

At present, selection of drug doses for metronomic chemotherapy is largely done empirically.^{8,9,41} However, recent studies suggest that several guiding principles can be applied. For example, myelosuppression should be avoided, as this has been shown to stimulate release of endothelial progenitor cells from the bone marrow. Drugs should be administered close to the highest tolerated metronomic dose in order to achieve maximal inhibition of angiogenesis. Studies in mice also have revealed that continuous oral dosing of cyclophosphamide does not appreciably alter the pharmacokinetics and metabolism of the drug.⁴²

In the present study, the dosage of cyclophosphamide selected (10 mg/m^2) was lower than those used in a previous studies.³³ This lower dosage was selected when it was found early in the study that continuous dosing of cyclophosphamide at higher dosages frequently led to adverse effects (eg, gastrointestinal adverse effects,

neutropenia), requiring dosage reduction. The 10 mg/m^2 dose of cyclophosphamide was well tolerated by most dogs. In dogs that did not tolerate daily dosing, adverse effects often were effectively controlled by switching to alternate day dosing. We could not determine from this study whether daily or alternate day dosing would be equally effective in delaying tumor recurrence.

Inhibition of tumor angiogenesis is likely to be 1 of the primary mechanisms of action of cyclophosphamide and piroxicam in the present study. However, immunologic effects could be equally important. For example, metronomic dosing of cyclophosphamide has been shown recently to reduce the number of regulatory T cells in mouse tumor models.^{15,16} Regulatory T cells are potent suppressors of antitumor immunity that are often increased in cancer patients, including dogs with cancer.⁴³ Other studies have shown that Treg depletion can help restore antitumor immunity.⁴⁴ In addition, piroxicam may exert direct inhibitory effects on tumor cells themselves, as has been reported for canine transitional cell carcinoma.²⁸

Although 40% of the dogs in the current study developed adverse effects at some point during treatment, in the majority of dogs the adverse effects were minor and related primarily to gastrointestinal signs (eg, vomiting, anorexia). Two dogs also developed evidence of renal functional impairment, which was thought to have been mediated primarily by the inhibitory effects of piroxicam on renal blood flow. In dogs with gastrointestinal or renal adverse effects, increasing the treatment interval to every other day dosing of both drugs usually was effective in resolving the adverse effects. Ten percent of dogs in the current study also developed hemorrhagic cystitis, a known complication of cyclophosphamide therapy in dogs.⁴⁵ This frequency is similar to that reported previously (9%) in a large series of dogs with lymphoma treated with cyclophosphamide as part of a multidrug treatment regimen.⁴⁵ It is however less frequent than we observed recently in a study of metronomic therapy with cyclophosphamide in dogs with hemangiosarcoma, in which 2 of 9 dogs (22%) developed sterile cystitis while receiving a higher dosage (25 mg/m^2) of cyclophosphamide.³³ Although valid comparisons of the frequency of cystitis cannot be made between the current study and the previous hemangiosarcoma study, the results of the current study suggest that the 10 mg/m^2 dose of cyclophosphamide may be safer and better tolerated for metronomic therapy in dogs.

Finally, the results of this study in dogs with STS and a recent study of dogs with hemangiosarcoma have important implications for application of this continuous 2-drug regimen to treatment of cancer in dogs in general. For example, continuous cyclophosphamide and piroxicam therapy also may be active in other tumors, particularly highly metastatic tumors such as osteosarcoma and melanoma. The largely negative results of recent trials of metronomic chemotherapy in humans, with or without COX inhibitors, which generally have included patients with large residual tumor burdens, suggest that these treatment protocols are more likely to be effective in animals with minimal residual tumor burdens.

Recent data from studies in rodent tumor models also suggest that inserting brief pulses of high-dose chemotherapy within a metronomic chemotherapy protocol can be more effective than metronomic treatment alone.⁴⁶ The benefit accrued from high-dose pulse therapy is thought to result from the ability of metronomic therapy to alter the tumor microenvironment, making it less favorable for support of tumor stem cells and increasing stem cell sensitivity to cytotoxic chemotherapy. Thus, dogs receiving continuous cyclophosphamide and piroxicam therapy may actually benefit from pulses of conventional high dose chemotherapy.

We believe the results presented here indicate that further evaluation of the metronomic cyclophosphamide and piroxicam protocol for treatment of a variety of cancers in dogs is warranted. Mechanistic studies are needed and should include assessment of circulating endothelial progenitor cells and regulatory T cells by flow cytometry. The metronomic cyclophosphamide and piroxicam protocol also potentially be adapted to combination treatment protocols with traditional chemotherapy, radiation therapy, or immunotherapy.

Footnote

^a GraphPad Prism, San Diego, CA

Acknowledgments

The authors acknowledge the assistance of Dr Lance U'ren and Ms Ally Ostrowski with data collection and analysis. These studies were supported in part by a grant from the NIH (CA86224-01).

References

- Folkman J. Role of angiogenesis in tumor growth and metastasis. *Semin Oncol* 2002;29:15–18.
- Folkman J. Angiogenesis. *Annu Rev Med* 2006;57:1–18.
- Zou W. Immunosuppressive networks in the tumour environment and their therapeutic relevance. *Nat Rev Cancer* 2005;5:263–274.
- Gately S, Kerbel R. Antiangiogenic scheduling of lower dose cancer chemotherapy. *Cancer J* 2001;7:427–436.
- Kerbel RS, Kamen BA. The anti-angiogenic basis of metronomic chemotherapy. *Nat Rev Cancer* 2004;4:423–436.
- Miller KD, Sweeney CJ, Sledge GW Jr. Redefining the target: Chemotherapeutics as antiangiogenics. *J Clin Oncol* 2001;19:1195–1206.
- Shimizu K, Oku N. Cancer anti-angiogenic therapy. *Biol Pharm Bull* 2004;27:599–605.
- Shaked Y, Emmenegger U, Man S, et al. Optimal biologic dose of metronomic chemotherapy regimens is associated with maximum antiangiogenic activity. *Blood* 2005;106:3058–3061.
- Lam T, Hetherington JW, Greenman J, et al. From total empiricism to a rational design of metronomic chemotherapy phase I dosing trials. *Anticancer Drugs* 2006;17:113–121.
- Mancuso P, Colleoni M, Calleri A, et al. Circulating endothelial cell kinetics and viability predict survival in breast cancer patients receiving metronomic chemotherapy. *Blood* 2006;108:452–459.
- Bocci G, Francia G, Man S, et al. Thrombospondin 1, a mediator of the antiangiogenic effects of low-dose metronomic chemotherapy. *Proc Natl Acad Sci USA* 2003;100:12917–12922.
- Folkman J. Endogenous angiogenesis inhibitors. *APMIS* 2004;112:496–507.
- Kamat AA, Kim TJ, Landen CN Jr., et al. Metronomic chemotherapy enhances the efficacy of antivascular therapy in ovarian cancer. *Cancer Res* 2007;67:281–288.
- Salem ML, Kadima AN, El-Naggar SA, et al. Defining the ability of cyclophosphamide preconditioning to enhance the antigen-specific CD8+ T-cell response to peptide vaccination: Creation of a beneficial host microenvironment involving type I IFNs and myeloid cells (1997). *J Immunother* 2007;30:40–53.
- Matar P, Rozados VR, Gonzalez AD, et al. Mechanism of antimetastatic immunopotentiality by low-dose cyclophosphamide. *Eur J Cancer* 2000;36:1060–1066.
- Ghiringhelli F, Menard C, Puig PE, et al. Metronomic cyclophosphamide regimen selectively depletes CD4+ CD25+ regulatory T cells and restores T and NK effector functions in end stage cancer patients. *Cancer Immunol Immunother* 2007;56:641–648.
- Gately S, Kerbel R. Therapeutic potential of selective cyclooxygenase-2 inhibitors in the management of tumor angiogenesis. *Prog Exp Tumor Res* 2003;37:179–192.
- Gately S. The contributions of cyclooxygenase-2 to tumor angiogenesis. *Cancer Metastasis Rev* 2000;19:19–27.
- Leahy KM, Ornberg RL, Wang Y, et al. Cyclooxygenase-2 inhibition by celecoxib reduces proliferation and induces apoptosis in angiogenic endothelial cells in vivo. *Cancer Res* 2002;62:625–631.
- Masferrer JL, Leahy KM, Koki AT, et al. Antiangiogenic and antitumor activities of cyclooxygenase-2 inhibitors. *Cancer Res* 2000;60:1306–1311.
- Yaqub S, Henjum K, Mahic M, et al. Regulatory T cells in colorectal cancer patients suppress anti-tumor immune activity in a COX-2 dependent manner. *Cancer Immunol Immunother* 2007;57:813–821.
- Sharma S, Yang SC, Zhu L, et al. Tumor cyclooxygenase-2/prostaglandin E2-dependent promotion of FOXP3 expression and CD4+ CD25+ T regulatory cell activities in lung cancer. *Cancer Res* 2005;65:5211–5220.
- Baratelli F, Lin Y, Zhu L, et al. Prostaglandin E2 induces FOXP3 gene expression and T regulatory cell function in human CD4+ T cells. *J Immunol* 2005;175:1483–1490.
- Mahic M, Yaqub S, Johansson CC, et al. FOXP3+ CD4+ CD25+ adaptive regulatory T cells express cyclooxygenase-2 and suppress effector T cells by a prostaglandin E2-dependent mechanism. *J Immunol* 2006;177:246–254.
- Buckstein R, Kerbel RS, Shaked Y, et al. High-dose celecoxib and metronomic “low-dose” cyclophosphamide is an effective and safe therapy in patients with relapsed and refractory aggressive histology non-Hodgkin’s lymphoma. *Clin Cancer Res* 2006;12:5190–5198.
- Spieth K, Kaufmann R, Gille J. Metronomic oral low-dose treosulfan chemotherapy combined with cyclooxygenase-2 inhibitor in pretreated advanced melanoma: A pilot study. *Cancer Chemother Pharmacol* 2003;52:377–382.
- Kesari S, Schiff D, Doherty L, et al. Phase II study of metronomic chemotherapy for recurrent malignant gliomas in adults. *Neuro Oncol* 2007;9:354–363.
- Mohammed SI, Bennett PF, Craig BA, et al. Effects of the cyclooxygenase inhibitor, piroxicam, on tumor response, apoptosis, and angiogenesis in a canine model of human invasive urinary bladder cancer. *Cancer Res* 2002;62:356–358.
- Knapp DW, Glickman NW, Mohammed SI, et al. Antitumor effects of piroxicam in spontaneous canine invasive urinary

bladder cancer, a relevant model of human invasive bladder cancer. *Adv Exp Med Biol* 2002;507:377–380.

30. Knapp DW, Richardson RC, Chan TC, et al. Piroxicam therapy in 34 dogs with transitional cell carcinoma of the urinary bladder. *J Vet Intern Med* 1994;8:273–278.

31. Knapp DW, Chan TC, Kuczek T, et al. Evaluation of in vitro cytotoxicity of nonsteroidal anti-inflammatory drugs against canine tumor cells. *Am J Vet Res* 1995;56:801–805.

32. Greene SN, Lucroy MD, Greenberg CB, et al. Evaluation of cisplatin administered with piroxicam in dogs with transitional cell carcinoma of the urinary bladder. *J Am Vet Med Assoc* 2007;231:1056–1060.

33. Lana S, U'Ren L, Plaza S, et al. Continuous low-dose oral chemotherapy for adjuvant therapy of splenic hemangiosarcoma in dogs. *J Vet Intern Med* 2007;21:764–769.

34. Thrall DE, Gillette EL. Soft-tissue sarcomas. *Semin Vet Med Surg (Small Anim)* 1995;10:173–179.

35. Mauldin GN. Soft tissue sarcomas. *Vet Clin North Am Small Anim Pract* 1997;27:139–148.

36. Withrow SJ. Soft tissue sarcomas. *Vet Q* 1998;20(Suppl 1):S16–S17.

37. Forrest LJ, Chun R, Adams WM, et al. Postoperative radiotherapy for canine soft tissue sarcoma. *J Vet Intern Med* 2000;14:578–582.

38. Vail DM, MacEwen EG. Spontaneously occurring tumors of companion animals as models for human cancer. *Cancer Invest* 2000;18:781–792.

39. Stempak D, Gammon J, Halton J, et al. A pilot pharmacokinetic and antiangiogenic biomarker study of celecoxib and

low-dose metronomic vinblastine or cyclophosphamide in pediatric recurrent solid tumors. *J Pediatr Hematol Oncol* 2006;28:720–728.

40. Lamerato-Kozicki AR, Helm KM, Jubala CM, et al. Canine hemangiosarcoma originates from hematopoietic precursors with potential for endothelial differentiation. *Exp Hematol* 2006;34:870–878.

41. Maraveyas A, Lam T, Hetherington JW, et al. Can a rational design for metronomic chemotherapy dosing be devised? *Br J Cancer* 2005;92:1588–1590.

42. Emmenegger U, Shaked Y, Man S, et al. Pharmacodynamic and pharmacokinetic study of chronic low-dose metronomic cyclophosphamide therapy in mice. *Mol Cancer Ther* 2007;6:2280–2289.

43. Biller BJ, Elmslie RE, Burnett RC, et al. Use of FoxP3 expression to identify regulatory T cells in healthy dogs and dogs with cancer. *Vet Immunol Immunopathol* 2007;116:69–78.

44. Curiel TJ, Coukos G, Zou L, et al. Specific recruitment of regulatory T cells in ovarian carcinoma fosters immune privilege and predicts reduced survival. *Nat Med* 2004;10:942–949.

45. Charney SC, Bergman PJ, Hohenhaus AE, et al. Risk factors for sterile hemorrhagic cystitis in dogs with lymphoma receiving cyclophosphamide with or without concurrent administration of furosemide: 216 cases (1990–1996). *J Am Vet Med Assoc* 2003;222:1388–1393.

46. Shaked Y, Emmenegger U, Francia G, et al. Low-dose metronomic combined with intermittent bolus-dose cyclophosphamide is an effective long-term chemotherapy treatment strategy. *Cancer Res* 2005;65:7045–7051.