

Continuous Low-Dose Oral Chemotherapy for Adjuvant Therapy of Splenic Hemangiosarcoma in Dogs

Susan Lana, Lance U'ren, Susan Plaza, Robyn Elmslie, Daniel Gustafson, Paul Morley, and Steven Dow

Background: Hemangiosarcoma (HSA) is a highly metastatic and often rapidly fatal tumor in dogs. At present, conventional adjuvant chemotherapy provides only a modest survival benefit for treated dogs. Continuous oral administration of low-dose chemotherapy (LDC) has been suggested as an alternative to conventional chemotherapy protocols. Therefore, we evaluated the safety and effectiveness of LDC using a combination of cyclophosphamide, etoposide, and piroxicam as adjuvant therapy for dogs with stage II HSA.

Hypothesis: We hypothesized that oral adjuvant therapy with LDC could be safely administered to dogs with HSA and that survival times would be comparable to those attained with conventional doxorubicin (DOX) chemotherapy.

Animals: Nine dogs with stage II splenic HSA were enrolled in the LDC study. Treatment outcomes were also evaluated retrospectively for 24 dogs with stage II splenic HSA treated with DOX chemotherapy.

Methods: Nine dogs with stage II splenic HSA were treated with LDC over a 6-month period. Adverse effects and treatment outcomes were determined. The pharmacokinetics of orally administered etoposide were determined in 3 dogs. Overall survival times and disease-free intervals were compared between the 9 LDC-treated dogs and 24 DOX-treated dogs.

Results: Dogs treated with LDC did not develop severe adverse effects, and long-term treatment over 6 months was well-tolerated. Oral administration of etoposide resulted in detectable plasma concentrations that peaked between 30 and 60 minutes after dosing. Both the median overall survival time and the median disease-free interval in dogs treated with LDC were 178 days. By comparison, the overall survival time and disease-free interval in dogs treated with DOX were 133 and 126 days, respectively.

Conclusions: Continuous orally administered LDC may be an effective alternative to conventional high-dose chemotherapy for adjuvant therapy of dogs with HSA.

Key words: Cyclophosphamide; Doxorubicin; Etoposide; Piroxicam; Tumor.

Hemangiosarcoma (HSA) is a malignant tumor of dogs that probably arises from endothelial stem cells and exhibits very aggressive biological behavior.¹⁻⁴ Even with complete surgical excision of the primary tumor, metastasis often occurs early in the postsurgical period and survival times are typically short. For example, the median overall survival time for dogs with stage I or II HSA treated with surgery alone was reported to be 86 days.⁴

Adjuvant treatment with chemotherapy, particularly with anthracycline-based drugs such as doxorubicin (DOX), has been reported to result in modest improvements in survival times.^{1,5-7} However, the prognosis remains poor for dogs with HSA. Typical median survival times after surgery and chemotherapy are 6 months or less. For example, Ogilvie et al⁵ reported a median overall combined survival time of 172 days for dogs with all stages of HSA treated with DOX chemotherapy.

Recent attempts to improve outcomes in dogs with HSA by adjuvant chemotherapy have focused on chemotherapy dose intensification, use of nonspecific

immune stimulation, or addition of angiogenesis inhibitors such as minocycline to traditional chemotherapy regimens.^{7,8} However, neither DOX dose intensification nor addition of minocycline were found to produce significant improvement in overall survival times compared with treatment with DOX alone.^{7,8} In contrast, a significant improvement in survival was observed in dogs treated with an immune modulator (liposome-encapsulated muramyl tripeptide phosphatidylethanolamine [L-MTP-PE]) combined with chemotherapy (median survival time, 162 days) compared with dogs treated with chemotherapy alone (median survival time, 96 days), but survival times were still relatively short.⁹ Thus, there remains a need for improved adjuvant therapy for preventing metastases in dogs with HSA.

Continuously administered LDC (metronomic or antiangiogenic dosing chemotherapy) is a promising alternative to conventional cancer chemotherapy protocols.¹⁰⁻¹³ Unlike traditional chemotherapy, the primary target of antiangiogenic chemotherapy is the tumor vasculature itself (specifically, the host endothelial cells) rather than the tumor cells.¹¹ Such an approach has several potential advantages, including the greater genetic stability of normal endothelial cells relative to tumor cells and the relative inability of nontransformed endothelial cells to develop resistance to chemotherapy drugs. Several different classes of chemotherapy drugs have demonstrated antiangiogenic activity *in vitro* and *in vivo*.¹² In early studies in mouse tumor models, cyclophosphamide administered at conventional high doses markedly increased endothelial cell apoptosis, even before the onset of tumor cell apoptosis.¹⁰ However, the tumor vasculature still underwent significant regeneration during the 2- to 3-week interval

From the Animal Cancer Center, Department of Clinical Sciences (Lana, Plaza, Morley, Dow) and the Department of Microbiology, Immunology, and Pathology (U'ren, Dow), Colorado State University, Ft Collins; Veterinary Cancer Specialists, Englewood, CO (Elmslie); and the Department of Pharmacology, University of Colorado Health Sciences Center, Denver (Gustafson).

Reprint requests: Steven Dow, DVM, MS, PhD, DACVIM, Department of Clinical Sciences, Colorado State University, Ft. Collins, CO 80523; e-mail: sdow@colostate.edu.

Submitted February 11, 2007; Accepted February 12, 2007.

Copyright © 2007 by the American College of Veterinary Internal Medicine

0891-6640/07/2104-0012/\$3.00/0

between chemotherapy doses. In contrast, when cyclophosphamide was given in a continuous, low-dose schedule, significant antiangiogenic activity persisted throughout the treatment period and was associated with control of tumor growth, even when tumor cells resistant to cyclophosphamide were assessed.¹⁰

Several mechanisms may account for the antiangiogenic effects of metronomic chemotherapy dosing. For one, dividing endothelial cells may have a unique sensitivity to low doses of chemotherapy, particularly to drugs such as microtubule inhibitors, as has been demonstrated *in vitro*.¹¹ Other studies have suggested that circulating endothelial progenitor cells from the bone marrow may be targeted by LDC.^{11,13–17} In addition, blood vessel growth may be altered indirectly by increasing production of antiangiogenic factors such as thrombospondin-1.¹⁸

Orally administered etoposide given in a low-dose schedule has been reported to have some efficacy against drug resistant tumors in human neuro-oncology patients.^{19–21} Although etoposide for use in humans is toxic in dogs when administered intravenously at high doses, the drug is thought to be potentially less toxic if administered orally.^{22,23}

The nonsteroidal anti-inflammatory drug (NSAID) piroxicam also has demonstrated significant activity against a variety of types of cancer in dogs.^{24–27} The effects of piroxicam on tumor cells in dogs have been evaluated extensively, as has the interaction of piroxicam with chemotherapy in dogs.^{26,28,29} Although the effects of piroxicam on tumor angiogenesis have not been extensively investigated, there is some evidence that inhibition of cyclooxygenase (COX) enzymes COX 1 and COX 2 by NSAIDs can interfere with endothelial cell tube formation and vascular endothelial growth factor (VEGF) production.^{30,31} Moreover, orally administered piroxicam is now commonly included in treatment protocols for a variety of different tumors of dogs.

Therefore, we conducted a study of orally administered LDC in dogs with splenic HSA. We hypothesized that, based on our previous clinical experience, LDC would be safe and effective in dogs with HSA. To test this hypothesis, we assessed the safety of long-term treatment with LDC in dogs with HSA and compared adverse effects to those in dogs treated with conventional DOX chemotherapy. In addition, treatment outcomes in dogs treated with LDC or with DOX chemotherapy were compared. The results of these studies suggested that LDC may be a useful alternative to conventional IV DOX chemotherapy for adjuvant therapy of dogs with splenic HSA.

Materials and Methods

Study Population

This study was approved by the Institutional Animal Care and Use Committee at Colorado State University, and informed owner consent was obtained before dogs were included in the study. Patients with histologically confirmed HSA of the spleen without obvious metastases at the time of surgery (stage II HSA) were eligible for entry into the study, whereas patients with stage III

Table 1. Patient population characteristics for dogs with stage II hemangiosarcoma treated with low-dose continuous chemotherapy (LDC) or conventional doxorubicin (DOX) chemotherapy.

Parameter	LDC group (n = 9)	DOX group (n = 25)
Age (y)	10.0 (10.0); 7–12	9.0 (9.9); 7–17
Weight (kg)	35.0 (33.1); 24.5–45.4	30.9 (31.8); 14–56.8
Sex		
Male intact	1	2
Male, neutered	6	12
Female, neutered	2	10

disease (measurable metastasis or multifocal disease) were excluded (Table 1). Dogs were treated by veterinary oncologists at the Animal Cancer Center, Colorado State University, Ft Collins, or at the Veterinary Cancer Specialists, Englewood, Colorado. Dogs were staged according to a modified World Health Organization system based on thoracic radiographs, abdominal ultrasound, exploratory laparotomy, and echocardiogram. Treatment was initiated 2 weeks after surgical splenectomy.

For the LDC study, 12 dogs with stage II splenic HSA were randomized in a 3 to 1 ratio into either the LDC treatment group (LDC group; 9 dogs) or the DOX-only treatment group (DOX group; 3 dogs), using a preassigned block randomization table. For comparison of survival times and disease-free intervals, we also retrospectively identified 21 dogs matched for tumor stage (stage II splenic HSA) that had been treated with DOX only at the same institutions and by the same oncologists over the past 10 years, including 6 dogs treated within the past 2 years. For evaluation of safety and adverse effects, data from the 3 dogs in the LDC study randomized to the DOX group were combined with data from the 6 recently treated DOX dogs. These 6 dogs were included in this analysis because they had been enrolled (and randomized into a control arm) in another study and had been actively monitored for adverse effects of DOX chemotherapy. For statistical analysis of treatment outcomes data, survival and disease-free interval data from the 9 dogs noted above were combined with survival and disease-free interval data from an additional 15 historical disease-matched and DOX-treated dogs (treated in the past 10 years at the 2 participating institutions) to form one group of 24 DOX-treated dogs.

Low-Dose Continuous Chemotherapy

Dogs enrolled in the LDC study were treated with etoposide and cyclophosphamide administered daily on alternating 3-week cycles. Piroxicam was administered continuously daily throughout the 6-month treatment period. The decision to use this combination of drugs (cyclophosphamide, etoposide, piroxicam) was based on the advice of Dr. Mark Kieran (Dana Farber Cancer Institute, Boston, MA) and on previous human and mouse treatment protocols.²⁰

Etoposide was administered as an oral solution once daily for 3 weeks. This treatment schedule was selected (rather than alternating every other day administration with cyclophosphamide) so that toxicity could be more easily assigned to one or the other drug treatments. The etoposide solution was prepared as a suspension in Ora Sweet/Ora Plus^a suspending agent at a concentration of 10 mg/mL, using etoposide for injection.^b Etoposide was dosed at 50 mg/m² and was administered in 3-week cycles, alternating with cyclophosphamide. Cyclophosphamide was administered PO at a dose of 12.5 to 25 mg/m² per day orally for 3 weeks, in alternating 3-week cycles with etoposide. Piroxicam was administered PO on a daily basis throughout the study, at a dose of 0.3 mg/kg per day.

The 3-drug combination was continued for 6 months (28 weeks) or until disease recurrence and progression was noted.

Doxorubicin Chemotherapy

DOX was administered IV at a dose of 30 mg/m² every 2 weeks for an intended course of 5 treatments.

Evaluation of Toxicity, Followup, and Outcome

Toxicity was graded according to the Veterinary Cooperative Oncology Group Common Terminology Criteria for Adverse Events (VCOG-CTCAE).¹⁵ In the LDC group, CBCs were done before treatment and again on days 7, 14, and 21, and then every 3 weeks until week 27. Gastrointestinal toxicity and a quality-of-life assessment were based on a questionnaire given to the owners at 3-week intervals. Patients in the DOX treatment group had CBCs done every 2 weeks for the first 10 weeks, and then once every 3 months after that until week 27. Gastrointestinal toxicity and quality-of-life assessment were based on a questionnaire given to the owners on the same schedule. Disease progression was evaluated using 3-view thoracic radiographs and abdominal ultrasound in the LDC group at weeks 9, 18, 27, and 36 or as warranted by clinical signs. The same parameters were evaluated in the 9 dogs in the DOX group at weeks 8, 18, 27, and 36.

Etoposide Pharmacokinetics

In 3 patients, blood samples were taken after a single oral dose of 50 mg/m² for pharmacokinetic analysis of etoposide blood concentrations to ensure oral bioavailability. Serum samples were collected at the following time points after PO administration: 0.5 hours, 1 hour, 2 hours, 4 hours, and 24 hours. Samples were frozen at -80°C and stored until analysis. Analysis was performed using liquid chromatography mass spectroscopy/mass spectroscopy using a modified protocol described previously.³²

Statistical Analysis

Disease-free interval was calculated from the time of surgical removal of the tumor to the time of metastasis, and survival was defined from the time of surgery to the time of death. The Kaplan Meier product-limit method and the log rank test were used to assess statistical differences between the treatment groups. Dogs that died of nontumor disease were censored from the survival analysis. Analysis was done using Graphpad Prism software (San Diego, CA). A *P* value <.05 was considered statistically significant.

Results

Assessment of Toxicity in Dogs Treated with LDC or with DOX Only

Dogs in the LDC and DOX treatment groups were assessed for clinical evidence of serious toxicity (grade 3 or 4), as defined previously.³³ Overall, the frequency of mild (grade 1 or 2) toxicities was similar between both treatment groups (data not shown). None of the 9 dogs in the LDC treatment group developed grade 3 or 4 hematologic toxicities, nor did any of these dogs develop grade 3 or 4 gastrointestinal toxicities. Two dogs in the LDC group developed signs consistent with sterile hemorrhagic cystitis, a known complication of cyclophosphamide treatment in dogs.³⁴ One of these dogs had received 25 mg/m² cyclophosphamide during the study; hemorrhagic cystitis developed at 12 months, after the study had ended. The owner of this dog elected to

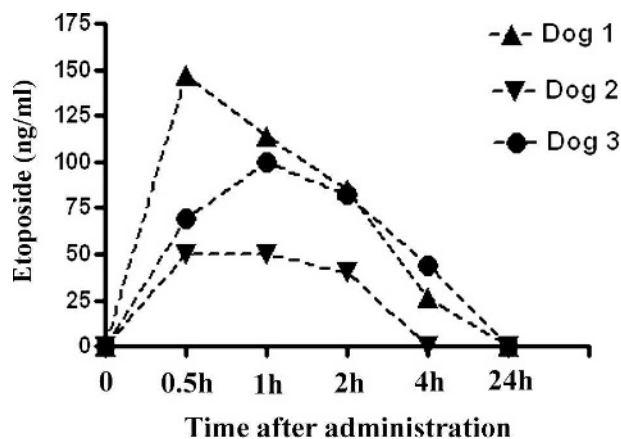


Fig 1. Blood concentrations of etoposide after oral administration. Serum concentrations of etoposide were determined at various time points over 24 hours after administration of a single oral dose of 50 mg/m² to 3 dogs with hemangiosarcoma, as described in methods.

continue LDC therapy using only etoposide and piroxicam. The second patient developed cystitis on week 18 of the study and was switched to PO etoposide plus piroxicam for the remaining 9 weeks of the study.

In the DOX group, none of the 9 treated dogs developed grade 3 or 4 hematologic toxicity. However, 3 of the dogs in the DOX group developed grade 3 or 4 gastrointestinal toxicity. None of the dogs in the DOX group developed cystitis. This frequency of hematologic and gastrointestinal adverse effects in dogs treated with DOX alone is consistent with what has been reported previously.³⁵

Absorption Kinetics After Oral Administration of Etoposide

Although etoposide has been administered systemically to dogs previously, oral absorption of the drug has not been evaluated previously in dogs.²² Therefore, absorption kinetics after PO dosing was evaluated in 3 HSA patients. In all 3 dogs, the peak serum concentrations of etoposide occurred between 30 minutes and 1 hour after dosing, and then declined thereafter (Fig 1). Drug concentrations in serum were detectable in 2 of 3 dogs at 4 hours after dosing, whereas etoposide concentrations were undetectable by 24 hours in all 3 dogs. These results indicate that etoposide is absorbed orally in dogs, but absorption appears to be somewhat variable; oral dosing seemed to achieve detectable levels though transient serum concentrations.

Outcome After Treatment with LDC or DOX

In the LDC group of 9 dogs, 6 dogs died of tumor metastasis, 1 dog died of unrelated causes (intervertebral disk disease), and 2 dogs were still alive at 63 and 498 days after diagnosis. In the combined group of 24 dogs treated with DOX, none of the dogs survived beyond 200 days. By Kaplan Meir survival analysis it was determined that the median overall survival time for dogs in the LDC group was 178 days, which was

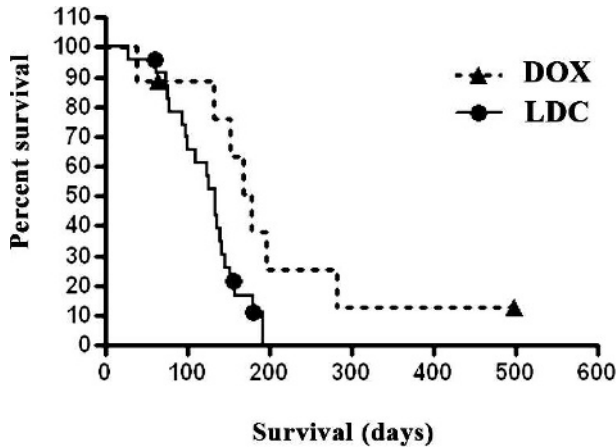


Fig 2. Survival times in dogs with hemangiosarcoma treated with adjuvant low-dose continuous chemotherapy (LDC) versus doxorubicin (DOX) chemotherapy. Survival times were determined and plotted for 9 dogs treated with LDC and 24 dogs treated with conventional DOX chemotherapy. The median survival time of 178 days for dogs in the LDC group was significantly different ($P = .03$) than the 133-day median survival time for dogs treated with conventional DOX chemotherapy.

significantly longer ($P = .03$) than the median overall survival time of 133 days for dogs in the DOX group (Fig 2). When disease-free intervals were compared, the median disease-free interval for dogs in the LDC group was 178 days, which was not statistically different ($P = .18$) from the median disease-free interval of 126 days for dogs in the DOX group (Fig 3).

Discussion

The major findings of this study were that low-dose continuous oral administration of 3 drugs (cyclophosphamide, etoposide, piroxicam) was well tolerated as adjuvant therapy for stage II splenic HSA in dogs. In addition, the results of this preliminary study involving a relatively small number of animals suggest that survival times after treatment with the 3-drug combination were at least as good as those obtained after conventional chemotherapy with DOX. Additional studies to assess the efficacy of continuous LDC for HSA or other metastatic tumors of dogs are therefore warranted.

Little progress has been made in treating HSA in dogs, and survival times for dogs with stage 2 or 3 disease are still relatively short (6 months or less) compared with those for dogs with other tumors.¹ Adding angiogenesis inhibitors to the treatment regimen has not improved survival times, and only immunotherapy in combination with chemotherapy has been shown to produce a significant increase in survival times.^{8,9}

The use of continuously administered LDC to inhibit tumor angiogenesis is a promising alternative for adjuvant therapy of HSA. For one, the neoplastic HSA cells are believed to arise from transformed endothelial cells and therefore may retain their susceptibility to certain antiangiogenic agents.³⁶ In addition, HSA tumors are themselves generally highly vascular-

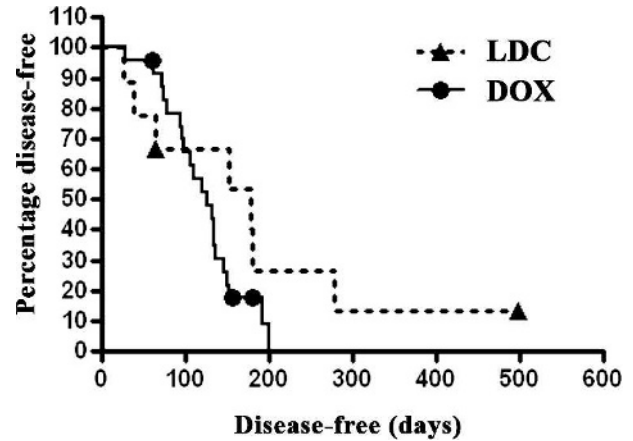


Fig 3. Disease-free intervals in dogs with hemangiosarcoma treated with adjuvant low-dose continuous chemotherapy (LDC) versus doxorubicin (DOX) chemotherapy. Disease-free intervals were determined and plotted for 9 dogs in the LDC group and 24 dogs in the DOX group. The median disease-free interval of 178 days in LDC group dogs was not significantly different ($P = .18$) from the 126-day median disease-free interval in dogs treated with DOX only.

ized and may therefore respond to inhibitors of normal endothelial cells. Moreover, the LDC treatment regimen is a relatively nontoxic and inexpensive alternative to conventional IV high-dose chemotherapy, with relatively little risk of typical chemotherapy adverse-effects. Therefore, LDC would be an attractive treatment option for HSA even if treatment outcomes were equivalent to those of conventional IV chemotherapy. In addition, the potential usefulness of LDC is likely not limited to the treatment of HSA, as we have also observed substantial treatment effects from continuous low-dose piroxicam and cyclophosphamide therapy in dogs with a variety of other tumors, especially sarcomas (Elmslie, RE; unpublished data).

Previous studies in rodent models and a few clinical trials in human beings have demonstrated the potential effectiveness of LDC.^{20,33} However, a clinical trial evaluating use of the LDC approach has not been previously reported in veterinary patients. Our study was designed to use a combination of drugs most likely to be used clinically by veterinary oncologists. As many dogs with cancer are now managed with continuously dosed piroxicam, that drug was included in the present study. At the doses of LDC used in this study, we did not observe appreciable toxicity, and in fact, the data suggested that toxicity may have been lower after treatment with LDC than with conventional DOX chemotherapy.

Although relatively small numbers of patients were treated in this preliminary study, it appeared that treatment with LDC was at least as effective as conventional DOX chemotherapy. Dogs treated with the LDC protocol experienced a statistically significant increase in survival times compared with historical data for control dogs matched for tumor stage and treated with DOX chemotherapy. Although comparisons with historical control groups are not always reliable in

predicting treatment outcomes, these results suggest that additional studies of LDC use for treating HSA and other metastatic tumors are warranted. We also observed that disease-free interval times were not significantly increased in dogs treated with LDC, whereas survival times were increased. The reasons for this apparent discrepancy are unclear, but may be related to a positive survival benefit of LDC treatment even after the tumor has recurred.

The design of our study included 3 drugs administered concurrently. Therefore, it was not possible to determine whether the observed effects of the 3-drug combination were attributable to the effects of a single drug or to the combined effects of all 3 drugs in the protocol. For example, the oral absorption of etoposide was very variable (see Fig 1) and therefore not all dogs may have attained adequate etoposide serum concentrations. Additional studies are indicated to address this issue. One possible explanation for the benefit observed with LDC therapy may be related to the duration of therapy (6 months) compared with the typical 10-week duration of DOX chemotherapy. It should also be noted that the survival times for dogs with HSA in both treatment groups were shorter than those reported in previous retrospective studies of dogs with HSA.^{5,7} The reasons for this discrepancy are not known, but may relate to differences in patient entry and staging criteria, or possibly to geographic factors that may have affected treatment outcomes. However, we believe the survival times reported here for dogs with carefully staged HSA are in fact representative of typical stage II splenic HSA patients treated in our region (Rocky Mountain region).

In future studies assessing antiangiogenic chemotherapy in dogs, it would also be helpful to include surrogate biomarkers for antiangiogenic effects, in addition to assessing clinical outcomes. Such assays could include *in vivo* angiogenesis assays (eg, tumor microvessel density or wound healing assays) and measurement of circulating antiangiogenic or proangiogenic factors such as thrombospondin-1 or VEGF. Assessment of the effects of treatment on numbers of circulating endothelial progenitor cells may be a particularly useful biological marker in assessing responses to treatment with continuously administered antiangiogenic agents.^{11,13,14} Through use of these surrogate markers it may also be possible to assess the relative contribution of any one drug in a multidrug combination.

Finally, it is also possible that LDC would be more effective if combined with standard high-dose DOX chemotherapy, an approach in which both the tumor cells and the tumor blood supply would be targeted simultaneously. The effectiveness of such an approach has been demonstrated recently in a mouse tumor model.¹⁵ One of the authors has treated several dogs with HSA and other tumors using LDC plus conventional DOX chemotherapy. The combined chemotherapy approach, although reasonably well tolerated, did, however, lead to an increased frequency of hematologic toxicities, particularly prolonged neutropenia (Elmslie, R; unpublished data). Alternatively, LDC might be more effective if combined with immunotherapy, using

either L-MTP-PE or liposome-DNA complexes.^[9,37] In conclusion, the results of the present study represent an important initial step in the development and evaluation of alternative adjuvant chemotherapy approaches for managing highly malignant tumors such as HSA in dogs.

Footnotes

^a Ora Sweet, Paddock Laboratories Inc, Minneapolis, MN

^b Topscar, SICOR Pharmaceuticals, Irvine, CA

Acknowledgments

The authors wish to acknowledge Dr Mark Kieran (Dana Farber Cancer Institute, Boston, MA) for assistance with study design and Ms. Julie Willer for excellent technical assistance. This study was supported by grants CA86224-01 and RR00707 from the National Institutes of Health.

References

1. Clifford CA, Mackin AJ, Henry CJ. Treatment of canine hemangiosarcoma: 2000 and beyond. *J Vet Intern Med* 2000;14:479–485.
2. Brown NO. Hemangiosarcomas. *Vet Clin North Am Small Anim Pract* 1985;15:569–575.
3. Smith AN. Hemangiosarcoma in dogs and cats. *Vet Clin North Am Small Anim Pract* 2003;33:533–552, vi.
4. Wood CA, Moore AS, Gliatto JM, et al. Prognosis for dogs with stage I or II splenic hemangiosarcoma treated by splenectomy alone: 32 cases (1991–1993). *J Am Anim Hosp Assoc* 1998;34:417–421.
5. Ogilvie GK, Powers BE, Mallinckrodt CH, et al. Surgery and doxorubicin in dogs with hemangiosarcoma. *J Vet Intern Med* 1996;10:379–384.
6. Sorenmo KU, Jeglum KA, Helfand SC. Chemotherapy of canine hemangiosarcoma with doxorubicin and cyclophosphamide. *J Vet Intern Med* 1993;7:370–376.
7. Sorenmo KU, Baez JL, Clifford CA, et al. Efficacy and toxicity of a dose-intensified doxorubicin protocol in canine hemangiosarcoma. *J Vet Intern Med* 2004;18:209–213.
8. Sorenmo K, Duda L, Barber L, et al. Canine hemangiosarcoma treated with standard chemotherapy and minocycline. *J Vet Intern Med* 2000;14:395–398.
9. Vail DM, MacEwen EG, Kurzman ID, et al. Liposome-encapsulated muramyl tripeptide phosphatidylethanolamine adjuvant immunotherapy for splenic hemangiosarcoma in the dog: a randomized multi-institutional clinical trial. *Clin Cancer Res* 1995;1:1165–1170.
10. Browder T, Butterfield CE, Kraling BM, et al. Antiangiogenic scheduling of chemotherapy improves efficacy against experimental drug-resistant cancer. *Cancer Res* 2000;60:1878–1886.
11. Kerbel RS, Kamen BA. The anti-angiogenic basis of metronomic chemotherapy. *Nat Rev Cancer* 2004;4:423–436.
12. Miller KD, Sweeney CJ, Sledge GW Jr. Redefining the target: chemotherapeutics as antiangiogenics. *J Clin Oncol* 2001;19:1195–1206.

13. Munoz R, Shaked Y, Bertolini F, et al. Anti-angiogenic treatment of breast cancer using metronomic low-dose chemotherapy. *Breast* 2005;14:466–479.
14. Shaked Y, Emmenegger U, Man S, et al. Optimal biologic dose of metronomic chemotherapy regimens is associated with maximum antiangiogenic activity. *Blood* 2005;106:3058–3061.
15. Shaked Y, Emmenegger U, Francia G, et al. Low-dose metronomic combined with intermittent bolus-dose cyclophosphamide is an effective long-term chemotherapy treatment strategy. *Cancer Res* 2005;65:7045–7051.
16. Mancuso P, Colleoni M, Calleri A, et al. Circulating endothelial cell kinetics and viability predict survival in breast cancer patients receiving metronomic chemotherapy. *Blood* 2006;108:452–459.
17. Bertolini F, Paul S, Mancuso P, et al. Maximum tolerable dose and low-dose metronomic chemotherapy have opposite effects on the mobilization and viability of circulating endothelial progenitor cells. *Cancer Res* 2003;63:4342–4346.
18. Bocci G, Francia G, Man S, et al. Thrombospondin 1, a mediator of the antiangiogenic effects of low-dose metronomic chemotherapy. *Proc Natl Acad Sci U S A* 2003;100:12917–12922.
19. Kieran MW, Turner CD, Rubin JB, et al. A feasibility trial of antiangiogenic (metronomic) chemotherapy in pediatric patients with recurrent or progressive cancer. *J Pediatr Hematol Oncol* 2005;27:573–581.
20. Kieran MW. Anti-angiogenic therapy in pediatric neuro-oncology. *J Neurooncol* 2005;75:327–334.
21. Ashley DM, Meier L, Kerby T, et al. Response of recurrent medulloblastoma to low-dose oral etoposide. *J Clin Oncol* 1996;14:1922–1927.
22. Hohenhaus AE, Matus RE. Etoposide (VP-16). Retrospective analysis of treatment in 13 dogs with lymphoma. *J Vet Intern Med* 1990;4:239–241.
23. Ogilvie GK, Cockburn CA, Tranquilli WJ, et al. Hypotension and cutaneous reactions associated with intravenous administration of etoposide in the dog. *Am J Vet Res* 1988;49:1367–1370.
24. Knapp DW, Richardson RC, Chan TC, et al. Piroxicam therapy in 34 dogs with transitional cell carcinoma of the urinary bladder. *J Vet Intern Med* 1994;8:273–278.
25. Knapp DW, Glickman NW, Mohammed SI, et al. Antitumor effects of piroxicam in spontaneous canine invasive urinary bladder cancer, a relevant model of human invasive bladder cancer. *Adv Exp Med Biol* 2002;507:377–380.
26. Henry CJ, McCaw DL, Turnquist SE, et al. Clinical evaluation of mitoxantrone and piroxicam in a canine model of human invasive urinary bladder carcinoma. *Clin Cancer Res* 2003;9:906–911.
27. Mohammed SI, Bennett PF, Craig BA, et al. Effects of the cyclooxygenase inhibitor, piroxicam, on tumor response, apoptosis, and angiogenesis in a canine model of human invasive urinary bladder cancer. *Cancer Res* 2002;62:356–358.
28. Mutsaers AJ, Glickman NW, DeNicola DB, et al. Evaluation of treatment with doxorubicin and piroxicam or doxorubicin alone for multicentric lymphoma in dogs. *J Am Vet Med Assoc* 2002;220:1813–1817.
29. Boria PA, Murry DJ, Bennett PF, et al. Evaluation of cisplatin combined with piroxicam for the treatment of oral malignant melanoma and oral squamous cell carcinoma in dogs. *J Am Vet Med Assoc* 2004;224:388–394.
30. Qiu ZF, Maruyama K, Sunayama K, et al. Piroxicam-induced regression of intestinal adenomatous polyps in APC (delta474) mice. *J Invest Surg* 2003;16:71–81.
31. Salcedo R, Zhang X, Young HA, et al. Angiogenic effects of prostaglandin E2 are mediated by up-regulation of CXCR4 on human microvascular endothelial cells. *Blood* 2003;102:1966–1977.
32. Pang S, Zheng N, Felix CA, et al. Simultaneous determination of etoposide and its catechol metabolite in the plasma of pediatric patients by liquid chromatography/tandem mass spectrometry. *J Mass Spectrom* 2001;36:771–781.
33. Glode LM, Barqawi A, Crighton F, et al. Metronomic therapy with cyclophosphamide and dexamethasone for prostate carcinoma. *Cancer* 2003;98:1643–1648.
34. Charney SC, Bergman PJ, Hohenhaus AE, et al. Risk factors for sterile hemorrhagic cystitis in dogs with lymphoma receiving cyclophosphamide with or without concurrent administration of furosemide: 216 cases (1990–1996). *J Am Vet Med Assoc* 2003;222:1388–1393.
35. Ogilvie GK, Reynolds HA, Richardson RC, et al. Phase II evaluation of doxorubicin for treatment of various canine neoplasms. *J Am Vet Med Assoc* 1989;195:1580–1583.
36. Thamm DH, Dickerson EB, Akhtar N, et al. Biological and molecular characterization of a canine hemangiosarcoma-derived cell line. *Res Vet Sci* 2006;81:76–86.
37. U'Ren LW, Biller BJ, Elmslie RE, Thamm D, Dow SW. Evaluation of a novel tumor vaccine in dogs with hemangiosarcoma. *J Vet Intern Med* 2007;21:113–120.