



VETERINARY SPECIALTY & EMERGENCY HOSPITAL

3550 South Jason Street

Englewood, CO 80110

(303) 874-PETS (7387)

[www.vrcc.com](http://www.vrcc.com)



VETERINARY SPECIALTY & EMERGENCY HOSPITAL





## SPRING 2023 NEWSLETTER

### SPRING HAS SPRUNG!

Spring is finally here! Bring on the longer days, warmer weather, and loads of sunshine that accompany the season!

Our 2023 Spring newsletter is full of information for you.

Meet Angela, one of our Critical Care CVTs who is also the VRCC Training Director & Technician Intern Supervisor in the staff highlight section on page 2.

Check out our news and events section that has an update on our new building!

Our Spring DVM CE is set for the evening of May 18th at one of our favorite places - the Downtown Aquarium! Read more details below.

The Surgery team explains how they are here to support you, your hospital, and your patients in the Specialty Highlight section just to the right on this page.

We hope you'll enjoy this edition's case study about atrial fibrillation treatment via electrocardioversion written by Dr. Erika Pugh with the VRCC Cardiology team.

Cheers and Happy Spring!

Your VRCC Team

### SPRING DVM CE ANNOUNCEMENT!

VRCC is hosting our Spring DVM CE at the Downtown Aquarium on Thursday, May 18th!



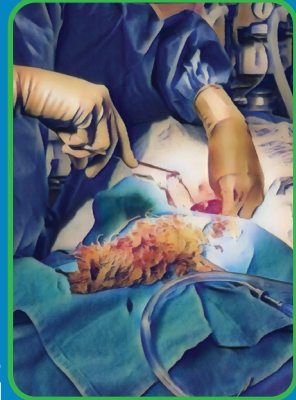
The event will start at 5pm for registration, with dinner and lectures to follow. Before registration and lectures, explore the Aquarium with complimentary admission for attendees! This event is free to attend; space is limited to 150 DVMs only, 3.0 CE credit hours offered.

Speakers and lectures topics will be announced in the coming weeks, so make sure you are on our email list! Registration is required and opens on **Tuesday, April 11th** and is on a first-come first-served basis. To register or get on our email list, send an email to Ruby Post at [rpost@vrcc.com](mailto:rpost@vrcc.com), or call 303-874-2053.

### PRACTICE HIGHLIGHT: VRCC SURGERY & ORTHOPEDICS

At VRCC Surgery & Orthopedics, we pride ourselves on our commitment to ensuring the safety and well-being of the animals in our care. We aim to ensure that each patient is provided with modern practices and technology to optimize outcomes and minimize patient morbidity.

Minimally invasive procedures provide opportunities to treat and diagnose patients while improving postoperative comfort and recovery. We offer basic laparoscopic procedures such as ovariectomies, gastropexies, and liver biopsies, among more advanced procedures for suitable patients. Thoracoscopic procedures available include pericardiectomy and thoracoscopic-assisted lung lobectomy. Arthroscopic procedures such as elbow medial coronoid process debridement and shoulder OCD debridement are best offered to younger patients at the beginning of the disease process to help reduce the progression of osteoarthritis. Our goal is to provide our clients and their pets with the highest quality care and support through every stage of life. We are passionate about creating a healthy, safe, and supportive environment and encourage you to reach out with any questions or concerns you may have.



Our skilled veterinarians and staff use modern technology and equipment to provide exceptional care and precision when performing delicate procedures. Our anesthesiologists can perform specialized local nerve blocks to decrease intra- and post-operative discomfort for improved patient outcomes. We also look forward to enhancing our medical care with an improved CT in our new location to aid in diagnosing and planning for advanced procedures.

We understand that many owners view major surgery with apprehension. Our consultation appointments are designed to inform owners about their pet's diagnosis and help guide them through the different treatment options. Dogs and cats have an important role in the modern family and we strive to provide compassionate and individualized care.

Our highly trained team is dedicated to providing quality specialty care for your clients and patients when they need it most. We are excited to enhance our care throughout the week and after-hours with the expansion of our surgery team. We look forward to returning to four full-time surgeons by the end of the year. Watch for future communications from us as we announce these exciting additions to our team. -

To reach the VRCC Surgery & Orthopedics team, call 303-874-2073, or email [surgery@vrcc.com](mailto:surgery@vrcc.com).

## STAFF HIGHLIGHT: CRITICAL CARE

### Angela Secchi, CVT, VRCC Critical Care, Training Director & Technician Intern Supervisor



Angela is one of the amazing Critical Care nurses at VRCC and has known FOREVER that veterinary medicine was her calling. Growing up in south Florida, she remembers reading a book of dog breeds so many times it eventually fell apart. After finishing high school, she made the decision to move to Wisconsin and start pursuing her career and education in the veterinary field. Angela attended the Milwaukee Area Technician College where she earned her Associate of Applied Science degree in Veterinary Technology in 2015. After working at a Wisconsin Specialty Hospital Angela decided to pick up and move to Colorado in November of 2019, where she then found VRCC. She has been a part of the VRCC Family since December of 2019.

Angela has a long-term plan and vision for where she is headed in her career in veterinary medicine. As she works towards her Veterinary Technician Specialist (VTS) in Critical Care, she has found a passion to teach and help others grow in their own positions. She is striving to develop training and teaching methods that help raise the standard of care for our patients. Angela has always set high expectations for herself and doesn't hesitate to hold those around her to the same standards. She is always willing to support another nurse in understanding the background of the treatments or procedures they are a part of, to foster excellent patient care.


Angela is the VRCC Training Director and our Technician Intern Supervisor. She is responsible for overseeing training protocols for all new technicians and technician interns that join the VRCC team. Angela has also been heavily involved in coordinating all of our in-house CE events for VRCC technicians and TAs.

There have been challenging cases that have had impacted Angela's outlook in the field, as well as some amazing heart-felt moments that have molded her into the nurse she is. One of her favorite cases that she has carried with her over the years was a critically ill dog, Slick, that spent 28 days in the hospital. After weeks of meticulous care and coming incredibly close to crossing the rainbow bridge, he was discharged to his family! Being a part of this success story only fueled the fire Angela continues to exhibit for her patients and her development as a nurse.


We asked Angela if she could do it all over again and pick a different career path – would she? Her answer: 10/10 – she would recommend a career in veterinary medicine and would do it all over again! Without a doubt she is in the right place and making a huge difference one patient, one client, and one team member at a time!

To reach the VRCC Critical Care Team, please call 303-874-7387, or email [criticalcare@vrcc.com](mailto:criticalcare@vrcc.com).

## VRCC NEWS & EVENTS

 We are super close to seeing clients and treating patients in our new building! This addition, just west of our main VRCC building, is located right off of Hampden Ave & Riverpoint Parkway. Our Oncology team will be relocating to the new building where we have a new state-of-the-art radiation administration unit for treating patients, along with an upgraded CT machine! Stay tuned for more information in the coming weeks about the official opening!



 Have you accessed our online referral management portal for shared patient records? Do you have feedback for us, questions about it, or would like some training via phone or on-site? Let us know and we'd be more than happy to help! Our front desk team, department client coordinators, and leadership team are familiar with how the portal works and can help you navigate through it to find your patient's records. Call us at 303-874-7387 to get some guidance with the portal, or visit the portal at <https://vrcc.rvetlink.com/login.asp> to get started.





**Dr. Erika Pugh, DVM,  
Cardiology Resident**

**VRCC Cardiology**

### Electrocardioversion for Atrial Fibrillation

Huginn, a 4-year-old male intact Irish Wolfhound presented to the VRCC Emergency Service on February 11, 2023, for further evaluation of an arrhythmia. Huginn was originally diagnosed with pneumonia in January and an arrhythmia was not noted at that time. He presented to his referring primary care veterinarian on 2/10/23 for recheck of his pneumonia and an arrhythmia was noted then. An electrocardiogram (ECG) was performed which was suspicious for atrial fibrillation so referral to VRCC was recommended.

Upon presentation to the VRCC Emergency Service, a cardiology consultation was obtained. Huginn was noted to have a heart rate of 208 beats per minute with an irregularly irregular rhythm with variable kinetic, symmetric femoral pulses and frequent pulse deficits. ECG revealed an irregular rhythm with absent P waves consistent with atrial fibrillation. An echocardiogram was performed which revealed a structurally and functionally normal heart. Since no structural abnormalities were identified, lone atrial fibrillation or atrial fibrillation secondary to the inflammation from the pneumonia was suspected.

Treatment of atrial fibrillation primarily consists of two options: heart rate control and rhythm control. Heart rate control involves leaving a patient in atrial fibrillation and giving oral antiarrhythmic medications to slow/control the atrial fibrillation heart rate. The goal with heart rate control is to have an average daily heart rate <125 beats per minute as measured by a 24-hour Holter monitor. The goal of rhythm control is to convert that patient back to a normal sinus rhythm. One method for rhythm control is electrocardioversion. With electrocardioversion, the goal is to convert the heart rate back to a normal sinus rhythm by delivering an electric shock to the heart while

the dog is anesthetized. Electrocardioversion can result in a normal sinus rhythm for a few seconds to a few years depending on the patient. Electrocardioversion is most successful in patients with no evidence of structural heart disease and when the atrial fibrillation is a new finding. Since the atrial fibrillation in this case was not appreciated on Huginn's original examination in January, acute atrial fibrillation was suspected, and he was deemed a good candidate for electrocardioversion. In preparation for the electrocardioversion, Huginn was started on oral amiodarone to increase the likelihood to obtain sinus rhythm with electrocardioversion.

Huginn presented the morning of March 2, 2023, for electrocardioversion for his atrial fibrillation. No new abnormalities were noted on physical examination and Huginn's systolic blood pressure was 164mmHg. Recheck thoracic radiographs revealed no evidence of residual pneumonia. A repeat ECG was consistent with atrial fibrillation (figure 1 below). The right and left cranial mid thorax was clipped and adult multifunctional electrodes were placed on either side of the chest. Methadone and midazolam were given IV for premedication. Anesthesia was induced using propofol and then maintained using isoflurane gas. Synchronous, biphasic electrocardioversion was utilized and the system was synchronized to the R wave of each complex. A shock of 75J was administered which resulted in conversion to a sinus rhythm with rare singlet atrial premature complexes. Huginn was recovered from anesthesia with no complications. He was discharged later the same day with carprofen for pain management. His owner was instructed to continue the amiodarone until a 1 month recheck ECG. A 2-day follow up call with his owner showed that Huginn was doing well at home with no concerns.

To reach VRCC Cardiology, call 303-874-2094, or email [cardio@vrcc.com](mailto:cardio@vrcc.com).

Figure 1: ECG for Huginn - pre and post shock

