







## FALL 2023 NEWSLETTER

### VRCC WELCOMES THE FALL SEASON!

Fall is on its way, and here at VRCC, we are ready for the sweater weather, the beautiful colors of the changing leaves around the state, extra-warm snuggles with our fur-babies, and cozy blankets that come with the season!

This issue of the VRCC newsletter highlights the VRCC Ophthalmology, Oncology, and Internal Medicine teams. It also provides up-to-date information on upcoming events, as well as, news about the hospital.

Learn more about Tanja Nuhsbaum, our Ophthalmologist, in the staff highlight section just to the right, on this page.

The VRCC Internal Medicine team discusses Nasal Aspergillosis in this edition's case study presented by Dr. Groth, on pages 2 and 3.

Learn more about our Oncology department in the Specialty highlight section below.

With cozy & colorful wishes this fall season,

The VRCC Team

happy  
fall y'all

### SPECIALTY HIGHLIGHT: ONCOLOGY

The oncology department at VRCC is very excited, as we get closer to our new Radiation Oncologist, Dr. Gregory Vernon, joining the team in November! As you have seen in previous communications, our new radiation building where Dr. Vernon will be seeing patients, is located at 3541 River Point Parkway in Sheridan, CO, 80110. At that location, we will be performing radiation treatments, as well as CT scans for diagnostic purposes and for radiation planning. Our CT has been upgraded to a helical CT, which is much faster than our current unit, resulting in our patients being under anesthesia for less time.

The medical oncology service will remain at our main VRCC building at 3550 S Jason Street in Englewood and employs two medical oncologists, Dr. Robyn Elmslie and Dr. Molly Benner. We continue to offer comprehensive cancer care with a multitude of services to aid in diagnosis, staging, and treatment of pets in their cancer journey including ultrasound, ultrasound guided aspirates, biopsy, cytology, digital radiography, CT, intravenous and oral chemotherapy.

Specialty Highlight . . . Continues on page 2

### STAFF HIGHLIGHT: OPHTHALMOLOGY

#### Tanja Nuhsbaum, DVM, MS, DACVO

My name is Tanja Nuhsbaum. I joined VRCC as a boarded ophthalmologist, in 2001. It is a pleasure to be highlighted in this VRCC Newsletter.

**Favorite fiction:** A Gentleman in Moscow, All the Light We Cannot See

**Favorite poets:** Rumi, Maya Angelou, Billy Collins, and Mary Oliver

**Favorite nonfiction topics:** Linguistics and ophthalmology (not combined)

**Favorite pastimes:** Coaching basketball, playing sports, cycling, being outside.

**Most inspired by:** Kids and individuals who help others.

**Most appreciative for:** My health, my family, my education, and the team at VRCC

**Favorite beverage:** Milk

**Favorite alcoholic beverage:** Rich, breathy, fruity Reds with a smooth finish

**Favorite food:** Anything that is prepared for me.

**Favorite candy:** Black licorice

**Favorite music:** Everything. Currently, AJR and Fleetwood Mac are top picks.

**Bucket list:** Visit Norway. Bike through Canada. Hike in the Dolomites.

**Personal goals:** Play the guitar and piano well.

**Personal fantasies:** Spontaneously jumping on-stage to fill in as a backup singer. (I am phenomenal.)

**Favorite ocular systems:** The ocular immune system and tear film fascinate me. Did you know each eye has separate immune system? Did you know that the tear film is a dynamic, avascular nutrient supply for the cornea?

**Favorite surgery:** Cataract removal surgery. My training path was a fast track into intraocular surgery with five talented surgical mentors, as such, cataract removal surgery is where my skill set shines.

Thank you for reading.  
Thank you for your referrals  
and thank you for your trust.  
I wish you well.

*VRCC Ophthalmology team  
members: Dr. Nuhsbaum,  
Shantell, Anne, and Stacie  
Goat Yoga*







VRCC Oncology team members: Cheryl, Sadie, Mandy, Jessica, & Katie at a recent team building trip to the Denver Zoo


The addition of the new building helps us continue our dedication to all of our clients and their pets' care through what can often be a frightening situation to navigate. Our relationships with our patients are just as strong and as important as with their owners, and we ultimately are 'treating' the entire family. When clients come in for an initial consultation, we offer the recommended diagnostic and treatment options based on their pet's individual case. Whether or not an owner chooses a treatment option, it is important to know that there is no wrong decision. We provide the information needed in order for an owner to make the best, most-informed decision possible for their pet and their family. The bottom line is that their pet is very much loved and cared for, and we feel fortunate to aid them in any way we can along their cancer journey. For example, if a chemotherapy treatment is chosen, there is no contract to be signed - it may be discontinued at any time, for any reason. Knowing this fact usually eases pet owners' minds.


We are always here for questions! To reach medical oncology, call 303-874-2054. To reach radiation oncology, call 303-874-3225. Both branches of oncology can be reached by emailing: [oncology@vrcc.com](mailto:oncology@vrcc.com).


## VRCC NEWS & ANNOUNCEMENTS


 VRCC Emergency & Critical Care welcome new doctors to the team! Dr. Lauren Palena joined us on September 1st, and Dr. Jamie Peake will be joining the ER team in early October. To reach the VRCC Emergency & Critical Care team, call 303-874-7387, or email: [emergency@vrcc.com](mailto:emergency@vrcc.com).

 VRCC Surgery welcomes two new surgeons! Dr. Samantha Stine and Dr. Alicia Nye both joined the VRCC Surgery family this September. To reach the VRCC Surgery team directly, call 303-874-2073, or email: [surgery@vrcc.com](mailto:surgery@vrcc.com).

 We appreciate when calls come in ahead of time to alert us of a patient being transferred to the Emergency service. We ask that the transferring/referring doctor be available for our DVM to chat with should any questions arise about the case. We always have an Emergency doctor on-site, so call at your convenience. Thank you for your partnership and referrals!

 Keep an eye out for information coming about our Fall DVM CE. This communication will be coming via email, so make sure you add [vrcc@vrcc.com](mailto:vrcc@vrcc.com) and [post@vrcc.com](mailto:post@vrcc.com) to your safe senders list!

 October 15 - 21 is National Veterinary Technician Appreciation week. Veterinary technicians are a vital part of our industry and do so much for our clients and patients. "THANK YOU!" to all Colorado veterinary technicians for all of your hard work!

 All VRCC Specialty Departments will be closed on Thursday, November 23rd in observance of Thanksgiving. Specialty departments will have limited hours on Black Friday, please call for availability. VRCC Emergency is available 24/7/365.

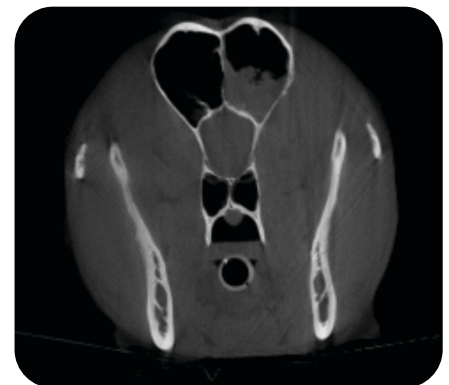


## CASE STUDY: INTERNAL MEDICINE

### Nasal Aspergillosis

Jasper was a 3-year-old castrated male Golden Retriever who was presented to the internal medicine service in 2020 with the primary complaint of unilateral nasal discharge and epistaxis. At the time of initial evaluation, there was also some depigmentation of the nasal planum on the same side as the discharge. He was clinically otherwise well at home. Initial diagnostics (CBC, chemistry, PT/PTT) were all within normal limits. The owner elected to proceed with a nasal CT scan with the primary differentials including nasal foreign body, nasal tumor, or fungal disease.

His first CT was performed in November 2020 (image 1, right). The CT showed multifocal soft tissue density in the left nasal cavity and left frontal sinus. There was also a significant amount of turbinate lysis present. These changes are most consistent with fungal disease. Rhinoscopy and biopsies confirmed the diagnosis of nasal aspergillosis.



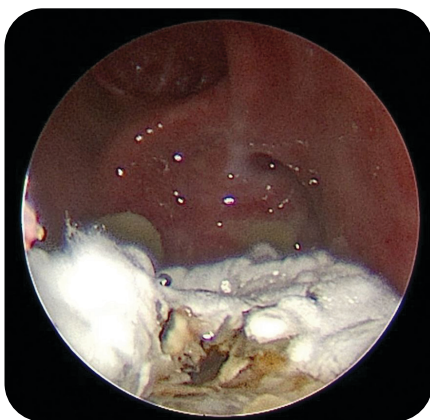CT scan of left frontal sinus with a large amount of soft tissue density in the sinus consistent with a fungal plaque



*Aspergillus fumigatus* is a ubiquitous fungus present worldwide in the environment. In dogs, this fungus typically affects the nasal passage and sinuses. There are some dog breeds including German Shepherds, Rottweilers, Retrievers, arctic breeds, and dolichocephalic breeds that seem to be predisposed. This may have to do with abnormal function of local immune system dysfunction. Systemic forms of aspergillosis infection are uncommon and typically only found in German Shepherds.

There are several factors that make treatment of sinonasal aspergillosis difficult. The lack of good blood supply to the fungal plaques is the primary barrier to efficacious systemic antifungal therapy. Topical therapy is typically with clotrimazole considered the most effective method of treatment, although this process is time-consuming and carries risks. The major complications with topical clotrimazole therapy are associated with the irritating nature of the clotrimazole itself and risk of aspiration post-procedure. Clotrimazole can cause pharyngeal/laryngeal swelling, although this is less common with the newer forms of the drug. Sinonasal aspergillosis typically causes widespread turbinate destruction in the nasal passage. Destruction of the cribriform plate can also occur. If it is present, topical therapy is not recommended due to risk of seizures.

In Jasper's case, we discussed the risks and benefits of topical therapy and the owner elected to proceed with topical therapy. A trephination was performed by a surgeon to allow access directly to the left frontal sinus. There was significant fungal disease present in the sinus (image 2, below). We performed debridement of the gross fungal disease both in the sinus and the nasal passage. After debridement, an infusion of liquid clotrimazole (1%) was instilled into the left frontal sinus and allowed to drain through the left nasal passage. After the liquid clotrimazole infusion was complete, the left frontal sinus was filled with clotrimazole cream to allow for longer contact time. Jasper recovered uneventfully from this procedure.

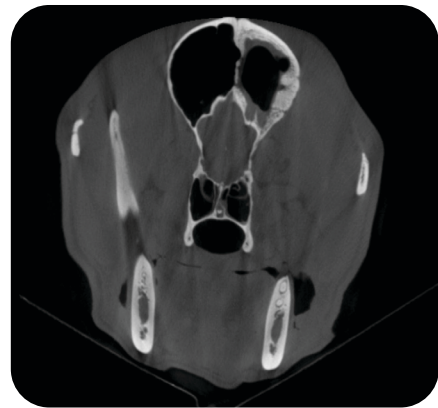


*Fungal plaque within the left frontal sinus prior to debridement*

Jasper clinically did well with almost complete resolution of his clinical signs for about 5 months following this procedure. Jasper was re-evaluated in May 2021 for relapsing nasal discharge. We elected to perform a repeat CT scan and topical clotrimazole therapy. His second CT

scan showed similar changes to the previous CT. The second trephination and clotrimazole therapy were performed and Jasper again did well for the procedure. Following the second procedure, Jasper was treated with a combination oral antifungal medications (terbinafine and voriconazole) for 3 months.

Jasper had resolved clinical signs again for about year but in May 2022. A third CT and clotrimazole treatment was performed in June 2022. The CT scan now showed improvement in the amount of disease present as well as sclerosis of the frontal sinus bones due to chronic infection (image 3, below). Jasper again did very well post procedure but had relapsing clinical signs about 7 months later.



*Final CT scan with persistent fungal plaque material and hyperostosis of the left frontal sinus*

After three topical treatments, the owner elected to not move forward with any additional procedures. We decided to start him on long term oral voriconazole. Jasper is now 8 months out from starting long term voriconazole and he is clinically normal with no nasal discharge and only occasional reverse sneezing.

This case illustrates the complicated and varied nature of treating sinonasal aspergillus. Topical therapy with clotrimazole is reported to be effective as a onetime treatment in up to 85% of dogs. Repeated treatments 3-4 weeks apart have been reported to improve overall cure rate, but this is not always possible. As stated above, oral therapy has historically not been effective due to lack of drug delivery to the site of infection. However, newer antifungals (voriconazole and posaconazole) have been shown to be more effective, especially when combined with terbinafine. Most antifungal medications are typically well tolerated by dogs. The most common side effects are GI upset. With prolonged use, hepatotoxicity can occur so serial liver value monitor is recommended for long term therapy. Medical management can be considered in cases in which there is cribriform plate destruction or in situations where topical therapy is not possible.

**By: Elizabeth Groth  
DVM, MS, Diplomate ACVIM  
VRCC Internal Medicine**

