



VETERINARY SPECIALTY & EMERGENCY HOSPITAL

3550 South Jason Street

Englewood, CO 80110

303-874-7387

www.vrcc.com



VETERINARY SPECIALTY & EMERGENCY HOSPITAL





WINTER 2022 NEWSLETTER

WINTERTIME IN COLORADO!

The beautiful snowy season of Colorado is on its way, and here at VRCC, we are ready for all things this time of year brings!

We would like to take this opportunity to wish you, your team, your clients & patients, and your families a warm, happy, and festive Holiday season.

This issue of the VRCC newsletter highlights VRCC Oncology, Ophthalmology, and Surgery. On the bottom of this page is a brief update on our new building. Please see our patient records reminder at the bottom of page 2.

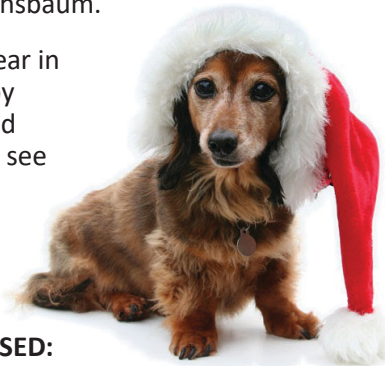Meet our team of Oncology supervisors in the Staff Highlight Section, on the right of this page.

Dr. Taylor Graville with the VRCC Surgery Department presents a case study discussing luxations on page 3.

Learn more about VRCC Ophthalmology in the specialty highlight section on page 2 written by Dr. Tanja Nuhsbaum.

We thank you for your partnership this year in caring for your clients and patients. Happy Holidays from everyone here at VRCC, and cheers to the New Year - we can't wait to see what comes in 2023!

Your VRCC Team



VRCC HOLIDAY HOURS

All VRCC Specialty departments are CLOSED:

- Christmas Eve (Saturday, December 24th)**
- Christmas Day (Sunday, December 25th)**
- New Year's Eve (Saturday, December 31st)**
- New Year's Day (Sunday, January 1st)**

VRCC Emergency is OPEN 24/7!

VRCC NEW BUILDING UPDATE

We are excited to share that our new building is almost ready to see clients and patients! We will share opening info via email when it is available - don't miss out! To make sure you are on our email list, or to sign-up, email our Referral Liaison Ruby Post at rpost@vrcc.com. You will be added to the list that gets hospital updates & news, as well as CE and event announcements.

Here is a picture of our current linear accelerator, Sid, dressed up for the season! Our new SRT unit is on-site at the new location and will be ready for use in early 2023!



STAFF HIGHLIGHT: ONCOLOGY

Cheryl Henry, CVT & Sadie Watson, CVT

Cheryl and Sadie are the dynamic duo that supervise the Oncology nursing team. While Cheryl manages the medical oncology side of the department, Sadie manages the radiation oncology side and is a trained radiation therapist. With their combined skill-set, they help the Oncology team provide comprehensive and compassionate care to their cancer patients.



Cheryl & Sadie

Cheryl has been with the Oncology department here at VRCC for 15 years. She moved here from Connecticut in 1998 after working retail for 5 years and even becoming a manager. After watching the show *Emergency Vets* on Animal Planet, she immediately knew she wanted to be an animal nurse, which would be much more rewarding. After graduating from Bel Rea in 1999 and doing her internship at Alameda East Veterinary Hospital (now a VCA), she jumped right into specialty practice and worked in internal medicine for 8 years, prior to making the move to VRCC. With this amount of experience, her knowledge and skills are crucial in the training of newly hired veterinary nurses. Cheryl believes that patience, kindness, and thoughtfulness are the key to patient care when providing chemotherapy treatments to our client's beloved pets, who are their children. When Cheryl is not at VRCC, she enjoys traveling the world, road and gravel biking, photography, and hanging out and playing with her 3 cats, Ritchey (15), Tommi and Jerri (17 month old kitten brothers).

Sadie has been with the Oncology department for 8 years. Sadie graduated from the Purdue Veterinary Technology program in 2009, and moved to Colorado in 2011. She enjoyed spending her clinical rotations in the oncology department at Purdue and set her goals to become an oncology nurse after moving to Colorado with her husband. She spent almost 5 years in general practice before applying for an open oncology technician position with VRCC. When Sadie is not at VRCC, she enjoys spending time with her husband, two little girls, kitty Wednesday and corgi Flynn. She enjoys the outdoors, music, and movies.



VRCC Oncology can be reached by calling 303-874-2054, or by emailing oncology@vrcc.com.

SPECIALTY HIGHLIGHT: OPHTHALMOLOGY

Respect, responsiveness, and relationship - The ophthalmology department is built on these three words. The reviews from our clients (10 out of 10) support that we are hitting our mark.



Ginger, an Ophthalmology patient, is one eyed and on top of the world!

When I wrote for the VRCC Spring 2022 newsletter earlier this year, I shared my struggles with burn-out. I received at least a dozen emails in response from you, my colleagues. New DVMs, 30-year veterans, male, female - our profession was well represented in these responses. Some shared their personal journey. Many related to my experience. All provided support, encouragement, and friendship. For those emails, I am grateful. They underscored that I work in the ranks of the best professionals in the world.

I am happy to report, in this year's post, that I enjoy my job at VRCC thoroughly. I receive 100% support from the administrative team and we have built a strong, thriving practice where, at the end of the day, team-members leave fulfilled. We help numerous patients and clients each day. We are appreciated and financially rewarded for our expertise and care, and, importantly, we still have energy and laughter to share with our family and our community when we get home after work. That old saying of "teamwork makes the dream work" is true.

So, here are some insights about the ophthalmology dream team at VRCC:

What we do: We provide full services for medical and surgical ophthalmology patients.

When we do it: Direct phone line is open Monday-Friday, 7am to 2pm. Workdays are three days per week. (Yes, we are still looking for another ophthalmologist, or three, to join our team. Recommendations from you are welcome.)

Who we can see: We have availability for new patients and can often work in same day emergencies through our day-time emergency department.

How VRCC supports our department: VRCC provides the best equipment, the best specialty-support team, and keeps a 22-year veteran in the ophthalmology chair. (Hey, that's me.)

How we give back: We provided practical CE lectures in ophthalmology, to regional DVMs, at each VRCC hosted event this year. We will continue to do so every year because we know that when we share what we have learned from others, the more patients and clients we help and, ultimately, that is what this profession is about.

Our favorite thing to do: It will always be cataract surgery. Restoring vision in a blind dog and the same-day reunion of a visual patient with the client after cataract surgery is nothing short of Hallmark worthy.

Our commitment to you: Again, respect, responsiveness, and relationship. We are always open to feedback.

Thank you for sharing your clients and patients with our team now and in the years to come.

To reach VRCC Ophthalmology, email eyes@vrcc.com, or call 303-874-2070.

Dr. Tanja Nuhsbaum
DVM, MS, Diplomate ACVO
VRCC Ophthalmology

VRCC PATIENT RECORDS REMINDER

Patient records can be accessed digitally via our referral management portal, rVetLink. rVetLink helps to streamline communication about patients that you refer here to VRCC. All patient reports, lab results, and image studies can be accessed via the portal here: <https://vrcc.rvetlink.com>. To get an account set-up, if you need some help with the portal, or have any questions, contact our Referral Liaison Ruby Post at rpost@vrcc.com, or 303-874-2053.



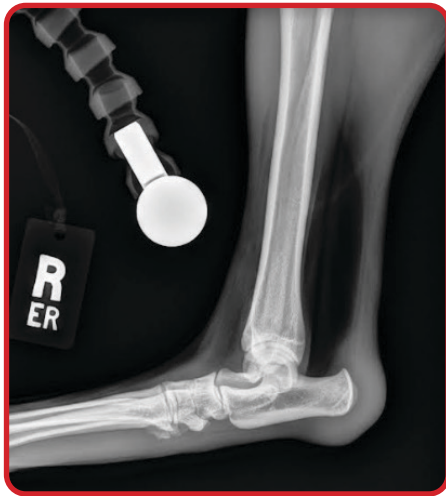CASE STUDY: SURGERY



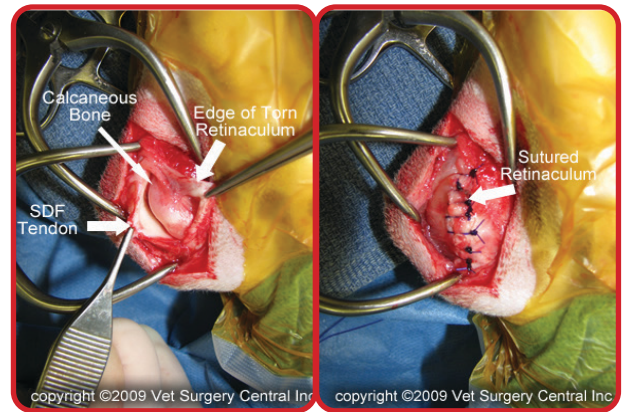
Taylor Graville, DVM
Practice Limited to Surgery
VRCC Surgery

Superficial Digital Flexor Tendon Luxations

Scout is a 1 year old female spayed German Shepherd mix that was presented to the VRCC Surgery & Orthopedics department. The presenting complaints included a one month history of intermittent left hind limb lameness, followed by a one week history of similar right hind limb lameness. In the hospital, no overt lameness was noted and was attributed to the patient's excitability. On exam, moderate to marked swelling over the calcaneal tuberosity was noted bilaterally and palpation of the tarsi confirmed the presence of effusion at the proximal aspect of the calcaneal tuberosity. Manipulation demonstrated bilateral lateral luxation of the superficial digital flexor tendons, which elicited a pain response in the patient. The remainder of physical and orthopedic exams were unremarkable, including the integrity of the common calcaneal tendon complexes. Radiographs of the tarsi were obtained to confirm the absence of bony abnormalities and demonstrated soft tissue swelling over the proximal calcaneal tuberosity with no other significant findings. Staged bilateral luxation repair was planned.



Surgery: The superficial digital flexor tendon's fibrocartilaginous cap over the calcaneal tuberosity was approached from the medial aspect. A large volume of clear peri-tendinous effusion was present in the calcaneal bursa and was drained when the distended medial retinacular tissues were incised. The retinacular tissue was significantly thickened. The superficial digital flexor tendon was identified and confirmed to be luxating to the lateral aspect of the calcaneal tuberosity. Approximately 7 mm of redundant tissue was excised, and allowed reduction of the SDFT to its position in the groove between the medial and lateral processes of the calcaneal tuberosity. 2-0 Prolene was used in a simple interrupted pattern to imbricate the medial retaining tissue. The SDFT tendon was palpated and could not be luxated in either direction. The surgical site was lavaged and closure was routine. Following closure, a lateral splinted bandage was applied to the distal limb/tarsus.



(Images courtesy of <https://www.animalsurgicalcenter.com>)

Discussion: Superficial digital flexor tendon luxations are an uncommon abnormality in the dog and are overrepresented in Shetland Sheepdogs or Collies, but can be seen in other breeds. It is most commonly diagnosed in young dogs. The dogs can be consistently lame due to the pain associated with the disease or can be intermittently lame, only when the tendon is luxated. Diagnosis is made based on a physical exam and the ability to manually luxate the tendon out of its normal position as it crosses over the groove in the proximal calcaneal tuberosity. The luxation can be in either direction, but most commonly the SDFT moves laterally due to the medial retaining structures being weaker than those on the lateral aspect. In chronic cases, the tendon may not be mobile and only swelling over the calcaneal tuberosity may be appreciated. Other conditions that must be considered and ruled out include orthopedic abnormalities within the tarsus and calcaneal tendon disruption.

Surgery is indicated in patients with chronic or severe lameness, and entails imbrication of the fibrocartilaginous pad and medial (or lateral, in the case of a medial luxation) retinacular structures using simple interrupted sutures. Unlike with medial patellar luxations, outcomes with SDFT luxations are improved when non-absorbable sutures are used. In patients with chronic disease and luxations that are not able to be manually reduced, surgical repair may also require release of the lateral retinacular structures. The joint should be immobilized for several weeks while the surgery site heals, prior to slow return to activity. In this case, a lateral splinted bandage was applied, but one report described a retaining pin in the calcaneus to stabilize the SDFT during healing. Outcomes are good with surgical treatment.

VRCC Surgery can be reached by calling 303-874-2073, or by emailing surgery@vrcc.com.

